Pathology – Research and Practice 212 (2016) 1174–1178

Contents lists available at ScienceDirect

Pathology – Research and Practice

journal homepage: www.elsevier.com/locate/prp

Original article

# Classification chaos in coeliac disease: Does it really matter?

Hilal Özakıncı[a], Ayça Kırmızı[a], Berna Savaş[a], Çağdaş Kalkan[b], İrfan Soykan[b], Hülya Çetinkaya[b], Zarife Kuloğlu[c], Aydan Kansu[c], Ödül Eğritaş Gürkan[d], Buket Dalgıç[d], Zeynep Şentürk[e], Arzu Ensari (MD, Ph.D.)[a,*]

[a] Departments of Pathology, Ankara University Medical School, 06100, Sıhhıye, Ankara, Turkey
[b] Departments of Gastroenterology, Ankara University Medical School, 06100, Sıhhıye, Ankara, Turkey
[c] Departments of Paediatric Gastroenterology, Ankara University Medical School, 06100, Sıhhıye, Ankara, Turkey
[d] Departments of Paediatric Gastroenterology, Gazi University Medical School, 06560, Yenimahalle, Ankara, Turkey
[e] Departments of Biostatistics, Ankara University Medical School, 06100, Sıhhıye, Ankara, Turkey

ARTICLE INFO

*Article history:*
Received 16 June 2016
Accepted 30 August 2016

*Keywords:*
Coeliac disease
Mucosal pathology
Classification

ABSTRACT

The spectrum of mucosal pathology in coeliac disease (CD), initially defined by Marsh in 1992 has been subjected to several modifications in the following years by Oberhuber, then by Corazza and Villanaci, and finally by Ensari. The present study, aimed to end the ongoing confusion regarding the classification of mucosal pathology in CD by applying all the classifications proposed so far on a large series of cases. A total of 270 duodenal biopsies taken from the distal duodenum of patients with a diagnosis of CD were included in the study. All biopsies were classified according to Marsh, Oberhuber, Corazza Villanaci, and Ensari classification schemes. For statistical analyses cases were divided into three groups: Group 1 included type 1 lesions in Marsh, Ensari, and Oberhuber and grade A in Corazza Villanaci classifications. Group 2 comprised of type 2 lesions in Marsh and Ensari classifications together with type2, type 3a and 3b lesions in Oberhuber classification and grade B1 lesions in Corazza Villanaci classification. Group 3 included type 3 lesions in Marsh and Ensari classifications, and type 3c lesions in Oberhuber, and grade B2 lesions in Corazza Villanaci classifications. The kappa value was 1.00 (excellent) for group 1, 0.53 (fair) for group 2 and 0.78 (excellent) for group 3 ($p < 0.0001$). These results suggest that any of the above classification system would serve similar purposes in the diagnosis of CD. Therefore, it is advisable that the pathologist should use the simplest reliable scheme.



## 1. Introduction

Coeliac disease (CD) is an autoimmune disorder of the small intestine precipitated by ingestion of wheat protein, gluten, in genetically susceptible individuals carrying the HLA-DQ2 or HLA-DQ8 genotype. Today, population-based studies indicate that approximately 0.5–1% of the Western European and Northern American populations suffer from CD [1,2].

Diagnosis of CD involves clinical, serological, genetic evaluation of the patient and histological examination of an adequate number of duodenal biopsies [2]. Clinical picture may be extremely variable ranging from classical malabsorption syndrome to cases with subtle and/or atypical symptomatology that are occasionally discovered during serological screening. Serological diagnosis is based on the detection of class IgA anti-tissue transglutaminase (anti-tTG) and anti-endomysial antibodies. In children, when anti-tTG antibody levels are very high (i.e. >10 times above the normal upper limit), and antibody specificity is absolute CD may be diagnosed without performing a duodenal biopsy [3]. In adults, however, biopsy is essential for the diagnosis of CD as seronegative cases have been reported with a prevalence of 6–22% [4].

Mucosal pathology involves a spectrum of abnormalities including intraepithelial lymphocytosis on one end, and completely flat mucosa on the other, none of which are specific for CD as they may be caused by a variety of disorders including autoimmune enteropathy, H.Pylori-associated duodenitis, irritable bowel syndrome, inflammatory bowel disease, bacterial overgrowth, graft-versus-host disease, and, drugs such as olmesartan [5]. Since patients with untreated CD, even if asymptomatic, are still at risk of developing various complications like osteoporosis, infertility, other autoimmune diseases including type 1 diabetes, autoimmune thyroiditis and autoimmune liver disease, and lymphoma [6],

* Corresponding author.
*E-mail address:* ensariarzu@gmail.com (A. Ensari).

http://dx.doi.org/10.1016/j.prp.2016.08.012
0344-0338/

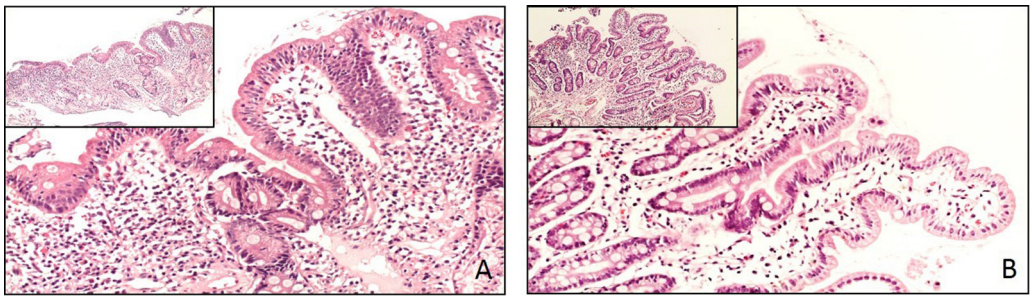


**Fig 1.** Patchy involvement in the same case. Decreased v/c ratio with increased IEL count in one piece (A) and normal v/c ratio and IEL count in the other piece (B) (H&E; X200, insets: X40, respectively).

pathologists, as members of the diagnostic team, are expected to classify mucosal pathology and make a differential diagnosis.

In 1992, after years of experimental and clinical research and tedious work, Marsh [7] defined the spectrum of mucosal pathology in CD which has received a warm welcome from pathologists worldwide and has been used as the histopathologic classification of CD. In the following years, Marsh's original classification has been subjected to modifications all proposed by pathologists including Oberhuber, Corazza Villanaci, and Ensari [8–10]. Recently, Villanaci suggested to classify CD as "non-atrophic" and "atrophic" in a more descriptive manner since both types of mucosal pathology can be observed in a large variety of conditions other than CD [11]. None of the above, however, became as popular as the original Marsh classification which elegantly illustrated the evolving mucosal pathology in CD. The resulting classification chaos has led to multiple problems for the practicing pathologist: understanding the criteria used for the classification scheme, choosing the most appropriate classification for his/her microscopic approach, and, more importantly, conveying a useful message to the clinician for the diagnosis and follow up of coeliac patients.

Hoping to end the chaos in the classification of CD, we investigated the concordance between the proposed classification schemes in a large cohort of coeliac patients in order to draw useful conclusions for practicing pathologists who deal with coeliac biopsies.

## 2. Material and methods

A cohort of 270 patients with a diagnosis of CD were collected during a period of ten years between 2000 and 2010 in Ankara University Medical School. There were 192 females and 78 males with a mean age of 38 years ranging from 4 to 82 years. Diagnosis of CD was made by a combination of histological, serological, and genetic criteria. Serologic tests comprised of anti-tissue transglutaminase 2 (tTG2) and/or anti-endomysial (EMA) IgA antibodies, and genotyping involved HLA DQ2-DQ8 haplotypes. All patients had serum anti-tTG2 IgA levels higher than the cutoff provided by the manufacturer and positive EMA. Multiple biopsies were taken from the distal duodenum at upper endoscopy. Biopsy samples fixed in 10% formaline were embedded mucosal surface upwards in paraffin and 4 μm-thick sections were cut at right angles to achieve vertical orientation and stained with H&E. Immunohistochemical staining was performed using anti-CD3 antibody (DAKO, Denmark) and streptavidin biotin-peroxidase for each case to evaluate the number of intraepithelial lymphocytes (IELs). At the time of diagnosis, all duodenal biopsies showed diffuse intraepithelial lymphocytosis (>25/100 enterocytes on CD3-stained slides) accompanied by no/varying degrees of villous abnormalities. Biopsies were re-evaluated by an experienced gastrointestinal pathologist with particular interest in CD (AE) and were classified using the four classification schemes including Marsh, Oberhuber, Corazza-Villanaci and Ensari. A semi-morphometric microscopic approach was employed: villous morphology was defined as "normal" when villous to crypt (v/c) ratio was three or above, as "shortened" when there were still visible villi and hyperplastic crypts with a v/c ratio less than three, and as "flattened" when no visible villi were present and the mucosa was completely flat.

Number of biopsy pieces were also noted to allow evaluation of patchiness of involvement. When there was patchy involvement, the case was classified with respect to the most severe degree of villous abnormality.

With this standardized approach all biopsies were classified according to Marsh, Oberhuber, Corazza Villanaci, and Ensari classification schemes. For statistical analyses cases were divided into three groups: Group 1 comprised of type 1 lesions in Marsh, Oberhuber and Ensari, and grade A in Corazza Villanaci classifications. Group 2 included type 2 lesions in Marsh, Oberhuber and Ensari classifications together with type 3a and 3b lesions in Oberhuber classification and grade B1 lesions in Corazza Villanaci classification. Group 3 consisted of type 3 lesions in Marsh and Ensari classifications, and type 3c lesions in Oberhuber classification and grade B2 lesions in Corazza Villanaci classification (see Table 1).

Statistical analyses were designed to evaluate concordance of the classifications by kappa, Fleiss' kappa statistics [12] using SPSS version 15.0 for Windows and R programme. The strength of agreement for the kappa coefficient was classified as poor when kappa values were <0.40, fair when they ranged from 0.40 to 0.59, good when values were between 0.60 and 0.74, and kappa values between 0.75 and 1.0 were termed as excellent agreement. A $p$-value of <0.05 was considered statistically significant.

## 3. Results

Duodenal biopsies consisted of 2–11 pieces with a mean of 3.24 gender or ±1.04 biopsy pieces. Thirty seven percent of the cases had 2 biopsy pieces while 63% of the cases had 3 or more biopsy pieces. Eighty cases (30%) showed a completely normal mucosal architecture with intraepithelial lymphocytosis, while 37 cases (13%) had shortened villi, and 153 cases (57%) presented with flat mucosae. Patchiness was assessed in all cases and was found in 54 specimens (20%) (Fig. 1).

On re-evaluation of the biopsies for classification, if the v/c ratio was normal (i.e.≥3), biopsy was classified as type 1 in Marsh, Oberhuber and Ensari classifications and grade A in Corazza Villanaci classification. A biopsy with normal villi but hyperplastic crypts with no change in v/c ratio was classified as type 2 according to Marsh and Oberhuber classifications. If there was villous shortening and crypt hyperplasia, biopsy was classified as type 3a or 3b in Oberhuber classification and grade B1 in Corazza Villanaci and as type 2 in Ensari classifications while complete flatness of the mucosa with

**Table 1**
The groups in the present study according to classifications.

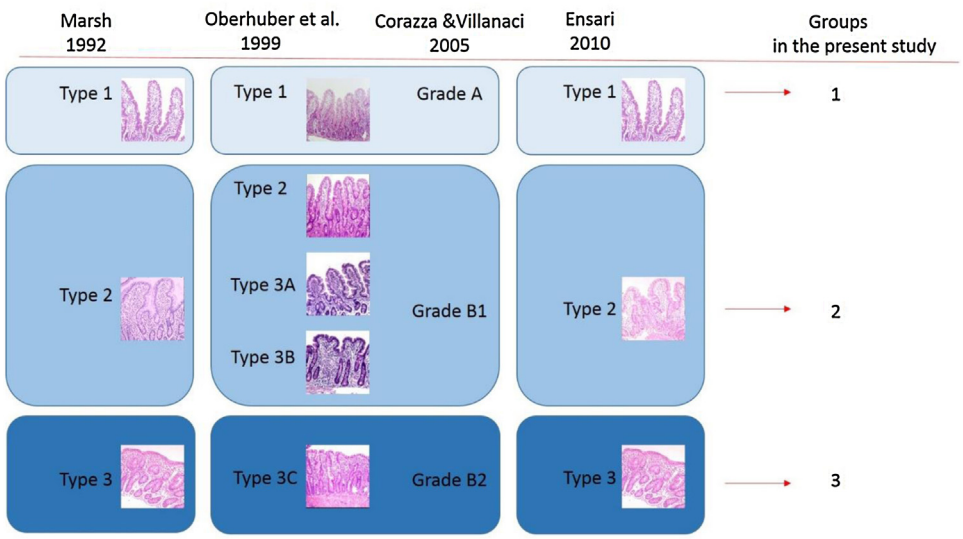


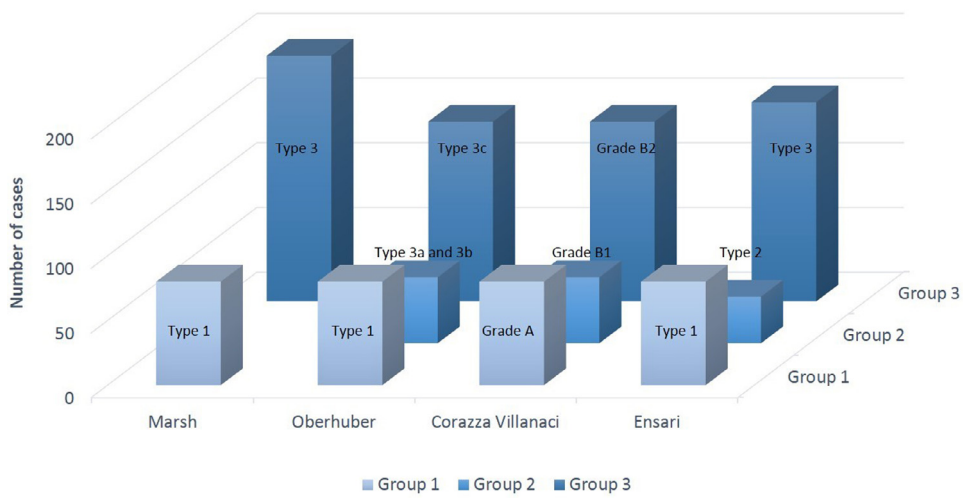


**Fig. 2.** Classification of cases according to four schemes included in the study.

no visible villi was compatible with type 3c in Oberhuber classification, grade B2 in Corazza Villanaci and as type 3 in both Marsh and Ensari classifications. The results of the re-evaluation revealed that 30% of the cases were classified as type 1 and/or grade A in all classification schemes used in the study. Seventy percent of cases were type 3 according to Marsh classification while 51% of cases were type 3c in Oberhuber classification and grade B2 in Corazza Villanaci classification and 57% of patients were type 3 according to Ensari classification (Fig. 2). Nineteen percent of cases were type 3a and 3b in Oberhuber and grade B1 in Corazza Villanaci classifications. There was no case classified as type 2 in Marsh or Oberhuber classifications while 13% of cases were classified as type 2 in Ensari classification.

The kappa value was 1.00 (excellent) for group 1, 0.53 (fair) for group 2 and 0.78 (excellent) for group 3 ($p < 0.0001$). Concordance of the three classification schemes (Ensari, Oberhuber and Corazza Villanaci) with Marsh was good, whereas Ensari, Oberhuber and Corazza Villanaci classification schemes were in excellent concordance with each other. The kappa and p values and confidence interval were summarized in Table 2.

**Table 2**
Concordance of classification schemes and case groups.

| Classification | Kappa | P | CI |
|---|---|---|---|
| Marsh-Oberhuber | 0,65 | <0.0001 | 0.57–0.74 |
| Marsh-Corazza Villanaci | 0,65 | <0.0001 | 0.57–0.74 |
| Marsh-Ensari | 0,73 | <0.0001 | 0.66–0.81 |
| Oberhuber- Corazza Villanaci | 1,00 | <0.0001 | 0.86–0.95 |
| Ensari-Oberhuber | 0.90 | <0.0001 | 0.86–0.95 |
| Ensari- Corazza Villanaci | 0.90 | <0.0001 | 0.86–0.95 |
| Groups | Kappa | p | CI |
| Group 1 | 1 | <0.0001 | 0.94–1.00 |
| Group 2 | 0.53 | <0.0001 | 0.48–0.58 |
| Group 3 | 0.78 | <0.0001 | 0.73–0.82 |
| | Fleiss' Kappa | | |
| Overall | 0.80 | <0.0001 | 0.76–0.87 |

## 4. Discussion

We have entered the era of new tools which serve to reduce the power of intestinal biopsy as a gold standard for the diagnosis of

CD. The reasons for this are several including, (i) the presence of mucosa sensitized to gluten without showing any visible mucosal alteration by routine microscopy ii) there are cases with gluten sensitivity or non-coeliac gluten intolerance with a similar clinical picture but absence of serologic positivity and normal intestinal mucosa or "microscopic enteritis" [13]. However, it is still considered essential in the diagnostic work-up of adult CD and cannot totally be replaced by serology in many clinical settings. Analysis of multiple biopsies is important as patchiness of the lesion has been reported and recent work suggests that different degrees of severity may be present, even in the different fragments of the same biopsy. Patchiness was reported in the range of 2%–53% in previous studies [14,15]. Though, the number of biopsy pieces was suboptimal for few of the cases included in the present study, the majority of the cases had >3 biopsy pieces and allowed us to determine the presence of patchiness observed in 20% of cases. This finding is in accordance with the international recommendations for taking multiple biopsies (at least four) from the duodenum [16] which will increase the possibility of detecting subtle mucosal changes. In the presence of variations in the degree of mucosal pathology the pathologist should report the most severe abnormality.

Marsh [7] defined the spectrum of mucosal pathology in gluten sensitivity which received a worldwide welcome from the pathologists and was since used as the histopathologic classification of CD. Soon after the original Marsh, modifications were proposed by several investigators including Oberhuber, Corazza Villanaci, and Ensari [8–10]. In the original Marsh classification, infiltrative (type 1), hyperplastic (type 2), and destructive (type 3) lesions were described morphologically. Type 1 consisted of normal mucosal architecture with IEL infiltration, whereas type 2 was characterized by crypt hyperplasia in addition to type 1. Type 3 was the characteristic flat mucosa with decreased v/c ratio [7]. Oberhuber's modification included subgrouping of Marsh type 3 lesion as 3A (mild villous atrophy), 3B (marked villous atrophy) and 3C (completely flat mucosa) [8]. Unfortunately, degree of changes in v/c ratio was based on subjective definitions such as "minor or moderate degrees of shortening and blunting of the villi" or "short tent-like remainders of the villi". Surprisingly, however, Oberhuber's modification found space in the pathology world despite its subjectivity. Later, Corazza and Villanaci, in a more simplified manner, classified coeliac lesions as grade A (non-atrophic), and grade B (atrophic). Grade B lesions were further subgrouped into B1 (mild atrophy) and B2 (severe atrophy) in a rather subjective fashion [9]. However, this proposal failed to gain interest from the pathologists many of whom continued to use the original Marsh while only few preferred Oberhuber's modified version. Indeed, Marsh classification doubled the number of citations received by Oberhuber's modification by 1283 vs 656 [17]. Ensari's proposal [10], though based on the original Marsh scheme, had two main arguments: firstly, following the steps of Marsh it avoided the term "atrophy" to define villous shortening. Highlighting "atrophy" as the major feature of CD fails to describe the condition of most patients, who often present with milder lesions devoid of "atrophy"or more appropriately, villous flattening [10]. It is, indeed, the mild mucosal abnormalities that deserve attention since they may easily be overlooked by the pathologists and when found may be related to other conditions as well as CD [18]. Secondly, a clarification was proposed for the definition of the original Marsh type 2 lesion which is almost never seen in routine biopsies unlike Marsh's time-dose related gluten challenge studies which allowed him to observe mucosal pathology in a dynamic manner [19]. In real life, however, when there is crypt hyperplasia, villi look somewhat shortened due to a decreased v/c ratio in relation to the mucosae without crypt hyperplasia. These arguments formed the basis of the "new" version of the "old" Marsh classification in which types 1 and 3 were identical to the original Marsh, namely intraepithelial lymphocytosis and flat mucosa, respectively, while type 2 was redefined as mucosa with villous shortening and crypt hyperplasia as well as intraepithelial lymphocytosis [10]. In support of this view, the results of the present study demonstrated that there was no case classified as type 2 in the large series of cases evaluated by either Marsh or Oberhuber classifications while some cases were classified as type 2 in Ensari classification. Moreover, illustrations of most type 2 cases presented in publications clearly demonstrate villous shortening in mucosae showing crypt hyperplasia [20–22]. Cummins et al. showed that mucosae classified as Marsh type II and as Oberhuber type IIIa were, indeed, very similar morphometrically, both with shortened villi [23].

## 5. Conclusions

There is sufficient evidence in the literature to state that there is no definite correlation between the degree of mucosal damage and severity of clinical symptoms in CD [24–26]. However, it is still important for the clinician to be informed about the histopathologic appearance of the mucosa in order to relate serology and other laboratory findings to the clinical picture. Therefore, it is crutial that the pathology report explains mucosal pathology in a descriptive manner which may or maynot include a classification scheme. Though, these classification schemes seem to be practical in clinical work, grouping may be challenging as minor histologic changes can easily be missed. It should also be born in mind that all the above classifications are largely dependent on the correct orientation of the biopsy specimens. Since the results of the present study have clearly demonstrated that the above classification systems have more similarities than differences, and that they would serve similar purposes, it would be fair to suggest that the practicing pathologist should go for the most "user-friendly"classification available.

## References


[1] P.H.R. Green, S. Krishnareddy, B. Lebwohl, Clinical manifestations of celiac disease, Dig. Dis. 33 (2015) 137–140.
[2] E. Tonutti, N. Bizzaro, Diagnosis and classification of celiac disease and gluten sensitivity, Autoimmun. Rev. 13 (2014) 472–476.
[3] S. Husby, S. Koletzko, I.R. Korponay-Szabo, M.L. Mearin, A. Phillips, R. Shamir, R. Troncone, K. Giersiepen, D. Branski, C. Catassi, M. Lelgeman, M. Maki, C. Ribes-Koninckx, A. Ventura, K.P. Zimmer, European Society for Pediatric Gastroenterology Hepatology, and Nutrition guidelines for the diagnosis of coeliac disease, J. Pediatr. Gastroenterol. Nutr. 54 (2012) 136–160.
[4] J.F. Ludvigsson, J.C. Bai, F. Biagi, T.R. Card, C. Ciacci, P.J. Ciclitira, P.H. Green, M. Hadjivassiliou, A. Holdoway, D.A. van Heel, K. Kaukinen, D.A. Leffler, J.N. Leonard, K.E. Lundin, N. McGough, M. Davidson, J.A. Murray, G.L. Swift, M.M. Walker, F. Zingone, D.S. Sanders, Diagnosis and management of adult coeliac disease: guidelines from the British Society of Gastroenterology, Gut 63 (2014) 1210–1228.
[5] L. Marthey, G. Cadiot, P. Seksik, P. Pouderoux, J. Lacroute, F. Skinazi, B. Mesnard, J.A. Chayvialle, G. Savoye, A. Druez, D. Parlier, V. Abitbol, M. Gompel, M. Eoche, E. Poncin, R. Bobichon, P. Colardelle, P. Wils, H. Salloum, S. Peschard, F. Zerbib, B. Meresse, N. Cerf-Bensussan, G. Malamut, F. Carbonnel, Olmesartan-associated enteropathy: results of a national survey, Aliment. Pharmacol. Ther. 40 (2014) 1103–1109.
[6] A. Vecsei, G. Amann, S. Hegenbart, M. Liedlgruber, A. Uhl, Automated Marsh-like classification of celiac disease in children using local texture operators, Comput. Biol. Med. 41 (2011) 313–325.
[7] M.N. Marsh, Gluten, major histocompatibility complex, and the small intestine. A molecular and immunobiologic approach to the spectrum of gluten sensitivity ('celiac sprue'), Gastroenterology 102 (1992) 330–354.
[8] G. Oberhuber, Histopathology of celiac disease, Biomed. Pharmacother. 54 (2000) 368–372.
[9] G.R. Corazza, V. Villanacci, Coeliac disease, J. Clin. Pathol. 58 (2005) 573–574.
[10] A. Ensari, Gluten-sensitive enteropathy (celiac disease): controversies in diagnosis and classification, Arch. Pathol. Lab. Med. 134 (2010) 826–836.
[11] V. Villanaci, The histologic classification of biopsy in celiac disease: time for a change? Dig. Liver Dis. 47 (2015) 2–3.
[12] J.L. Fleiss, Measuring nominal scale agreement among many raters, Psychol. Bull. 76 (1971) 378–382.
[13] K. Rostami, D. Aldulaimi, G. Holmes, M.W. Johnson, M. Robert, A. Srivastava, J.F. Flejou, D.S. Sanders, U. Volta, M.H. Derakhshan, J.J. Going, G. Becheanu, C. Catassi, M. Danciu, L. Materacki, K. Ghafarzadegan, S. Ishaq, M.

Rostami-Nejad, A.S. Pena, G. Bassotti, M.N. Marsh, V. Villanacci, Microscopic enteritis: bucharest consensus, World J. Gastroenterol. 21 (2015) 2593–2604.
[14] A. Ravelli, V. Villanacci, C. Monfredini, S. Martinazzi, V. Grassi, S. Manenti, How patchy is patchy villous atrophy? Distribution pattern of histological lesions in the duodenum of children with celiac disease, Am. J. Gastroenterol. 105 (2010) 2103–2110.
[15] D.C. Weir, J.N. Glickman, T. Roiff, C. Valim, A.M. Leichtner, Variability of histopathological changes in childhood celiac disease, Am. J. Gastroenterol. 105 (2010) 207–212.
[16] A. Rostom, J.A. Murray, M.F. Kagnoff, American Gastroenterology Association (AGA) Institute technical review on the diagnosis and management of celiac disease, Gastroenterology 131 (2006) 1981–2002.
[17] A.S. Pena, What is the best histopathological classification for celiac disease? Does it matter? Gastroenterol. Hepatol. 8 (2015) 239–243.
[18] I. Brown, M. Mino-Kenudson, V. Deshpande, G.Y. Lauwers, Intraepithelial lymphocytosis in architecturally preserved proximal small intestinal mucosa: an increasing diagnostic problem with a wide differential diagnosis, Arch. Pathol. Lab. Med. 130 (2006) 1020–1025.
[19] M.N. Marsh, D.E. Loft, V. Garner, D. Gordon, Time/dose responses of celiac mucosae to graded oral challenges with Frazer's fraction III of gliadin, Gastroenterol. Hepatol. 4 (1992) 667–673.
[20] P.H. Green, K. Rostami, M.N. Marsh, Diagnosis of coeliac disease, Best Pract. Res. Clin. Gastroenterol. 19 (2005) 389–400.
[21] S.R. Owens, J.K. Greenson, The pathology of malabsorption: current concepts, Histopathology 50 (2007) 64–82.
[22] W.P. Pais, D.R. Duerksen, N.M. Pettigrew, C.N. Bernstein, How many duodenal biopsy specimens are required to make a diagnosis of celiac disease? Gastrointest. Endosc. 67 (2008) 1082–1087.
[23] A.G. Cummins, B.G. Alexander, A. Chung, E. Teo, J.A. Woenig, J.B. Field, F.M. Thompson, I.C. Roberts-Thomson, Morphometric evaluation of duodenal biopsies in celiac disease, Am. J. Gastroenterol. 106 (2011) 145–150.
[24] A. Picarelli, R. Borghini, G. Donato, M. Di Tola, C. Boccabella, C. Isonne, M. Giordano, C. Di Cristofano, F. Romeo, G. Di Cioccio, A. Marcheggiano, V. Villanacci, A. Tiberti, A weaknesses of histological analysis in celiac disease diagnosis: new possible scenarios, Scand. J. Gastroenterol. 49 (2014) 1318–1324.
[25] P. Brar, G.Y. Kwon, I.I. Egbuna, S. Holleran, R. Ramakrishnan, G. Bhagat, P.H. Green, Lack of correlation of degree of villous atrophy with severity of clinical presentation of coeliac disease, Dig. Liver Dis. 39 (2007) 26–29.
[26] B. Zanini, F. Caselani, A. Magni, D. Turini, A. Ferraresi, F. Lanzarotto, V. Villanacci, N. Carabellese, C. Ricci, A. Lanzini, Celiac disease with mild enteropathy is not mild disease, Clin. Gastroenterol. Hepatol. 11 (2013) 253–258.