

Management of childhood appendicitis: laparoscopic versus open approach

Çocuklarda laparoskopik ve açık apendektomi sonuçlarının karşılaştırılması

Rahşan Vargün, Aydın Yağmurlu, Meltem Bingöl-Koloğlu, Hülya Özkan, Haluk Gökçora, Tanju Aktuğ, Hüseyin Dindar

Department of Pediatric Surgery, Ankara University School of Medicine, Ankara Turkey

Aim: Laparoscopic management of pediatric appendicitis remains controversial. A retrospective chart review was performed to compare laparoscopic versus open approach in the treatment of childhood appendicitis.

Patients and Methods: Three hundred thirty seven children who underwent appendectomy with preoperative diagnosis of appendicitis over a 36-month period were included to the study. Primary outcome measures were postoperative wound infection, intra-abdominal abscess formation and intestinal obstruction. Secondary outcome measures were the length of operation, time to oral feeding, analgesic need and hospitalization time.

Results: Total number of children in laparoscopy group was 126 (39.8%) whereas this number for open group was 188 (59%). There were 3 (1%) conversions in laparoscopy group. Mean length of operative time for laparoscopic (LA: 52 ±1.34 min), and open appendectomy (OA: 54 ± 1.27min), were similar (p>0.05). Time to full enteral feeding (OA: 24 ±1.1h, LA: 14±0.5h), analgesic usage (OA: 48±5h, LA: 24±5h) and length of hospitalization (OA: 3.9±0.1 day, LA: 2.8±0.1 day) were shorter in laparoscopic group compared to the open procedure (p<0.05). Early postoperative complication rate as wound infection (OA: 2.5%, LA: 0.3%), intra-abdominal abscess formation (OA: 1.3%, LA: 0.3%) were higher in OA group (p<0.05). Adhesive intestinal obstruction in need of re-operation was encountered in 5 (1.6 %) children in OA versus none in LA (p<0.05). Similar results were obtained for simple and complicated appendicitis separately.

Conclusions: Laparoscopic appendectomy is at least as safe and effective as open appendectomy in the management of childhood appendicitis. LA does not increase length of operation and offers a faster recovery. Postoperative complication rate is low compared to open approach.

Key words: **Appendicitis, laparoscopy, childhood**

Amaç: Çocukluk çağında laparoskopik apendektomi halen tartışmalıdır. Laparoskopik ve açık apendektomi yapılmış olan çocukların dosyaları geriye dönük olarak incelenip sonuçlar karşılaştırıldı.

Hastalar ve Yöntem: Apendisit tanısıyla 36 aylık sürede apendektomi yapılmış olan 337 çocuk çalışmaya dahil edildi. Ameliyat sonrası kesi yeri enfeksiyonu, karın içi abse gelişimi ve brid ileus çalışmanın birincil sonuç kriterleri olarak belirlendi. Çalışmanın ikincil sonuç kriterleri ameliyat süresi, oral besleme zamanı, ağrı kesici ihtiyacı ve hastanede kalış süresi olarak saptandı.

Bulgular: Çocukların 126'sına (%39.8) laparoskopik apendektomi (LA), 188'ine (%59) açık apendektomi (AA) yapıldı. Laparoskopik gruptaki üç hastada (%1) açık apendektomiye geçildi. Ameliyat süreleri LA (52±1.34 dk) ve AA'de (54±1.27 dk) benzerdi (p>0.05). Oral besleme zamanı (AA: 24 ±1.1saat, LA:14±0.5 saat), ağrı kesici ihtiyacı (AA:48±5 saat, LA:24±5 saat) ve hastanede kalış süresi (AA:3.9±0.1 gün, LA:2.8±0.1 gün) açısından gruplar karşılaştırıldığında LA grubunda daha kısa olduğu görüldü (p<0.05). Ameliyat sonrası erken dönem komplikasyon oranları karşılaştırıldığında, kesi yeri enfeksiyonu (AA:2.5%, LA: 0.3%), karın içi abse gelişimi (AA:1.3%, LA:0.3%) AA grubunda daha yüksek oranda gözlemlendi (p<0.05). LA grubunda brid ileus nedeniyle ikincil ameliyat gerekmezken, AA grubunda beş çocukta (%1.6) ameliyat gerektiren brid ileus gelişti (p<0.05). Gruplar akut ve komplike apendisit olarak ayrılıp karşılaştırıldığında da benzer sonuçlar alındı.

Tartışma: Çocukluk çağında laparoskopik apendektomi, en az açık apendektomi kadar güvenli ve etkilidir. Ameliyat süresini uzatmaz ve hızlı iyileşme sağlar. Açık apendektomi ile karşılaştırıldığında komplikasyon oranları daha azdır.

Anahtar sözcükler: **Apendisit, laparoskopi, çocuk**

Received: 22.12.2005 • Accepted: 08.03.2006

Corresponding author

Aydın Yağmurlu
Ankara Üniversitesi Tıp Fakültesi, Çocuk Cerrahisi Anabilim Dalı
06100 Dikimevi – Ankara, Turkey
Tel : +90 (312) 595 61 99
Fax : +90 (312) 362 6400
E-mail adress : eayagmur@medicine.ankara.edu.tr

Appendicitis is the most common surgical emergency in childhood (1). Open appendectomy has been the standard treatment for decades for both acute and complicated appendicitis and has proven safe and effective (2, 3). Semm's application of laparoscopy for the treatment of appendicitis has introduced an element of controversy to an otherwise well established treatment (4). Laparoscopic appendectomy has the intrinsic appeal that is shared by all minimal access surgery. This includes the potential for decreased post-operative pain, more rapid return to full activity and improved cosmesis. However there have been several studies suggesting that the laparoscopic approach results in possible increased length of operating time and postoperative complications compared to the open approach. These observations have been reported in both adults and children (5-12).

Despite these reported potential disadvantages, laparoscopic appendectomy has become a popular operation for acute and complicated appendicitis in children (5, 7, 11, 13, 14).

The purpose of our study was to compare the outcome of laparoscopic and open appendectomy in children with acute and complicated appendicitis in pediatric surgical center, which recently started to perform, minimally invasive procedures in children.

Patients and methods

Over a thirty-six months period, a total of three hundred thirty seven children with the diagnosis of appendicitis were analyzed in a retrospective chart review. Appendectomy was performed by either an open or laparoscopic technique based on individual surgeon preference. The type of procedure performed was determined by the preference of the attending surgeon with six surgeons contributing cases to the series. Each surgeon had a clearly preferred technique, which did not seem to be dependent upon patient characteristics. Five surgeons used a single technique throughout the series (one laparoscopic and four open). Additionally one other surgeon transitioned from exclusive use of open to exclusive use of laparoscopic during the series. One hundred twenty six (39.8%) of these children were treated with a laparoscopic approach and 188 (59%) had open appendectomy. Twenty patients whose histopathological results demonstrated no inflammation regarding to appendix were not included. Open appendectomy was performed through a right lower quadrant muscle-splitting incision. The appendix was ligated at the base and divided with or without (less than 1% of the children) inversion of the appendiceal stump. Irrigation was performed in 99% of the patients. The abdominal fascia was closed in layers.

Laparoscopic appendectomy was performed using a Veress needle for abdominal insufflation and placement of three abdominal access trocars. The meso-appendix was divided with electrocautery. The appendix was laparoscopically mobilized and tied at the base with endo loops and then divided. The appendix was then removed from the abdomen via the 12mm. umbilical trocar. The entire abdomen was inspected for contamination and typically vigorously irrigated in complicated appendicitis cases.

Children with perforated appendicitis or intraabdominal abscess formation were accepted as complicated appendicitis. Postoperatively, the patients with complicated appendicitis received IV fluid and parenteral broad-spectrum antibiotics. Children received a triple antibiotic regimen typically for 7 to 10 days. Oral antibiotics were also prescribed at the time of discharge for an additional week. A second-generation cephalosporine was used for prophylaxis during induction of anesthesia in acute appendicitis cases. Oral feeding was initiated and advanced as tolerated by the child.

In addition to demographic data, particular attention was given to the operative time, time to adequate oral intake, analgesic need and length of hospital stay. Length of operation was calculated from skin incision to completion of wound closure. The time to adequate oral intake was specifically defined as postoperative time period required for the child to tolerate two thirds of daily maintenance fluid by mouth. Postoperatively all patients pain assessment scores were recorded, and IV or oral analgesics were administered as required. Time to analgesic need was defined according to the requirement of analgesic administration. Length of hospital stay was defined as time of admission until time of discharge.

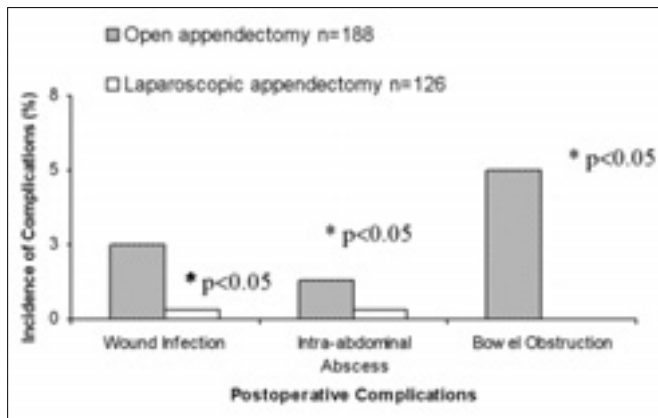
The primary outcome measures of this study were development of a wound infection, intra-abdominal abscess formation and bowel obstruction. Wound infection was defined as purulent drainage from the wound or a change in antibiotics secondary to inflammatory changes in the wound. Computerized tomography or ultrasonography reports were used to establish the diagnosis of intra-abdominal abscess formation. Bowel obstruction was defined as the patient requiring re-admission for gastrointestinal decompression or re-operation.

Comparison of LA versus OA for the same parameters was also performed separately in simple and complicated appendicitis.

The frequency of complications in the two groups was compared with the Chi-square test. Student's t test was utilized for comparing other continuous variables.

Table 1. Secondary outcome measures according to acute and complicated appendicitis

	Acute appendicitis (n=249)		Complicated appendicitis (n=68)		Total (n=317)	
	OA (n=144)	LA (n=105)	OA(n=44)	LA (n=22)	OA(n=188)	LA (n=126)
Operative time	50.6 ± 0.9min	52 ± 1.4 min	60 ± 3.5min	67 ± 3.5min	52 ± 1.34 min	54 ± 1.34 min
Time for analgesic need	36 ± 5 h	22 ± 5 h	58 ± 12 h	26 ± 4 h	48 ± 5 h	24 ± 5 h
Oral tolerance time	19 ± 0.5 h	13 ± 0.3 h	40 ± 3.8 h	19 ± 2.6 h	24 ± 1.1 h	14 ± 0.5h
Length of hospital stay	3.2 ± 0.1day	2.6 ± 0.1day	6.3 ± 0.5day	3.9 ± 0.4day	3.9 ± 0.1day	2.8 ± 0.1 day

**Figure 1.** Postoperative complication rates for groups

Results

Presenting symptoms and preoperative laboratory values were similar for both groups. Gender distribution was also similar in open and laparoscopic appendectomy groups with a male to female ratio of 2/1. In both populations the patients' ages ranged from 2 to 18 years. The mean age of the open group was 10.7±0.5 years versus 11.2±0.5 years for the laparoscopic group. Mean operative time was 54±1.27 minutes for open appendectomy group and 52±1.34 minutes for the laparoscopic group. This difference was not statistically significant ($p>0.05$). The mean time that the children required analgesic administration was 48±5 hours for the open appendectomy group and 24±5 hours for the laparoscopic group ($p<0.05$). The mean time to adequate oral intake was 24±1.1 postoperative hours for the open group versus 14±0.5 postoperative hours for the laparoscopy group ($p<0.05$). Children who underwent open appendectomy were hospitalized 3.9±0.1 days on average, whereas the laparoscopic appendectomy patients stayed 2.8±0.1 days. Similar results were obtained when LA and OA groups compared separately for simple and complicated appendicitis (Table 1).

Incidence of postoperative complications for groups is summarized in Figure 1. The most common complication

observed in the group of children who underwent open appendectomy was wound infection. Five (2.5%) of the patients in this group developed a superficial wound infection. In the laparoscopic appendectomy group only one patient developed a wound infection and it was located at the umbilical trocar site, where it was used for the removal of inflamed appendix. The difference between groups was statistically significant ($p<0.05$).

Four (1.3%) of the patients undergoing open appendectomy developed a postoperative intra abdominal abscess. Three of these patients had intra-abdominal abscess formation during the initial admission. One of these patients was re-hospitalized and treated with IV antibiotics. Three patients required percutaneous drainage with ultrasonographic guidance. In laparoscopic group only one patient developed an intra-abdominal abscess, which treated conservatively with IV antibiotics and percutaneous drainage with ultrasonographic guidance. The difference between the incidences of this complication was also statistically significant ($p<0.05$).

There were five patients in open appendectomy group who developed a postoperative adhesive bowel obstruction in need of re-operation as a complication. This incidence was 1.6% in the open group versus null in laparoscopic group ($p<0.05$).

All of the complications but two wound infections in open appendectomy group were encountered in patients with complicated appendicitis.

Discussion

Most of the controlled trials comparing laparoscopic versus open appendectomy in adults and children report significant advantages of the laparoscopic technique in reduced wound infection rate. This can be explained by the almost complete avoidance of abdominal wall contamination during laparoscopic procedures especially true for all forms of complicated appendicitis with local formation of pus (7, 10, 14-16).

Our results of laparoscopic appendectomy confirm the significantly lower rate of wound healing complications ($p < 0.05$). Only one patient developed a superficial wound-healing impairment at the umbilical trocar site. On the other hand, eight patients who underwent open appendectomy for appendicitis developed a superficial wound infection. These results were comparable to other published infection rates (12, 17).

Risk factors for the formation of intra-abdominal abscess remain controversial. There have been several reports suggesting the incidence of this complication is higher following laparoscopic appendectomy compared to open appendectomy in patients with complicated appendicitis (18). Classic open appendectomy data have identified three factors crucial to minimizing intra-abdominal abscess rates, including adequate preoperative resuscitation, appropriate peri-operative antibiotics and good surgical technique (18-20). The results of the presented study showed no increase in the incidence of postoperative intra-abdominal abscess after laparoscopic appendectomy, on the contrary the incidence for this complication was significantly lower than the open appendectomy group ($p < 0.05$). It has been suggested that the ligation of appendiceal base with staples as opposed to an endo-loop reduce the risk of spillage (11). All the patients in this series had their appendiceal stump ligated with endo-loops and only one patient developed an intra-abdominal abscess formation. Placing the detached appendix into an endo-bag prior to removal from the abdominal cavity reduces contact with visceral or fascial surfaces, minimizing intra-abdominal contamination. All the children who underwent laparoscopic appendectomy in this series had their inflamed appendix removed via the 12mm umbilical trocar and only one developed an intra-abdominal abscess. Ortega et al. (21) have reported that the incidence of bowel obstruction is higher in laparoscopic appendectomy for complicated appendicitis compared to the open approach. Incidence of postoperative adhesive bowel obstruction in our study was significantly higher in open approach versus laparoscopic appendectomy ($p < 0.05$).

One of the purported disadvantages of laparoscopic appendectomy is the longer operative times (10). Our results refute this notion. This study is one of the first, demon-

strating similar operating times with laparoscopic versus open appendectomy in the management of childhood appendicitis.

The time to start postoperative oral intake was not found to be different in children and adults undergoing laparoscopic versus open appendectomy in most of the published data (22, 23). Reintroduction of normal diet occurred earlier after laparoscopic than open appendectomy in a few studies (24). In our series, the children in the laparoscopic appendectomy group usually started taking adequate oral intake in the 14th postoperative hours compared to 24th postoperative hours for open appendectomy.

One of the major advantages of laparoscopic procedures reported to be the faster recovery and shorter length of hospital stay. There have been several reports suggesting the hospitalization was significantly shorter when the patient treated by laparoscopic appendectomy (12, 14-16, 25). The mean length of stay for the laparoscopic appendectomy group in the present series was almost 24 hours less than that for the open appendectomy group ($p < 0.05$). Since this was not a prospective trial, we believe that length of stay would be more determined by individual surgeon practices such as feeding advancement and discharge criteria than by operative technique. In the absence of a uniform protocol to regulated feeding and discharge, we believe these data would be misleading.

In summary, postoperative complications occurred in 7% of our patients. 2.8% of these complications were superficial wound infections. Laparoscopic appendectomy in children with appendicitis in this study is associated with a significant decrease in the rate of wound infection, intraabdominal abscess formation and postoperative adhesive intestinal obstruction. In our series laparoscopic appendectomy did not increase the operative time but leads to shorter hospital stay and quicker recovery.

As a conclusion, laparoscopic appendectomy is a safe alternative to traditional open approach and could be the procedure of choice for both acute and complicated appendicitis in childhood.

References

1. Addiss DG, Shaffer N, Fowler BS, et al. The epidemiology of appendicitis and appendectomy in the United States. *Am J Epidemiol* 1990; 132:910-925.
2. Fishman SJ, Pelosi L, Klavon SL, et al. Perforated appendicitis: prospective outcome analysis for 150 children. *J Pediatr Surg* 2000; 35:923-926.
3. Pearl RH, Hale DA, Molloy M, et al. Pediatric appendectomy. *J Pediatr Surg* 1995; 30:173-181.
4. Semm K. Endoscopic appendectomy. *Endoscopy* 1983; 15:59-64.
5. Canty TG, Collins D, Losasso B, et al. Laparoscopic appendectomy for simple and perforated appendicitis in children: the procedure of choice? *J Pediatr Surg* 2000; 35:1582-1585.
6. Frazee RC, Bohannon WT. Laparoscopic appendectomy for complicated appendicitis. *Arch Surg* 1996; 131:509-511;discussion 511-513.
7. Kokoska ER, Murayama KM, Silen ML, et al. A state-wide evaluation of appendectomy in children. *Am J Surg* 1999; 178:537-540.
8. Lavonius MI, Liesjarvi S, Ovaska J, et al. Laparoscopic versus open appendectomy in children: a prospective randomised study. *Eur J Pediatr Surg* 2001; 11:235-238.
9. Little DC, Custer MD, May BH, et al. Laparoscopic appendectomy: An unnecessary and expensive procedure in children? *J Pediatr Surg* 2002; 37:310-317.
10. Paya K, Fakhari M, Rauhofer U, et al. Open versus laparoscopic appendectomy in children: a comparison of complications. *Jsls* 2000; 4:121-124.
11. Steyaert H, Hendrice C, Lereau L, et al. Laparoscopic appendectomy in children: sense or nonsense? *Acta Chir Belg* 1999; 99:119-124.
12. Stoltzing H, Thon K. Perforated appendicitis: is laparoscopic operation advisable? *Dig Surg* 2000; 17:610-616.
13. Lintula H, Kokki H, Vanamo K. Single-blind randomized clinical trial of laparoscopic versus open appendectomy in children. *Br J Surg* 2001; 88:510-514.
14. Meguerditchian AN, Prasil P, Cloutier R, et al. Laparoscopic appendectomy in children: A favorable alternative in simple and complicated appendicitis. *J Pediatr Surg* 2002; 37:695-698.
15. Chung RS, Rowland DY, Li P, et al. A meta-analysis of randomized controlled trials of laparoscopic versus conventional appendectomy. *Am J Surg* 1999; 177:250-256.
16. Paya K, Rauhofer U, Rebhandl W, et al. Perforating appendicitis. An indication for laparoscopy? *Surg Endosc* 2000; 14:182-184.
17. Jess P. Acute appendicitis: epidemiology, diagnostic accuracy, and complications. *Scand J Gastroenterol* 1983; 18:161-163.
18. Katkhouda N, Friedlander MH, Grant SW, et al. Intraabdominal abscess rate after laparoscopic appendectomy. *Am J Surg* 2000; 180:456-459;discussion 460-461.
19. Reid RI, Dobbs BR, Frizelle FA. Risk factors for post-appendectomy intra-abdominal abscess. *Aust N Z J Surg* 1999; 69:373-374.
20. Temple LK, Litwin DE, McLeod RS. A meta-analysis of laparoscopic versus open appendectomy in patients suspected of having acute appendicitis. *Can J Surg* 1999; 42: 377-383.
21. Ortega AE, Hunter JG, Peters JH, et al. A prospective, randomized comparison of laparoscopic appendectomy with open appendectomy. Laparoscopic Appendectomy Study Group. *Am J Surg* 1995; 169:208-212;discussion:212-213.
22. Lejus C, Delile L, Plattner V, et al. Randomized, single-blinded trial of laparoscopic versus open appendectomy in children: effects on postoperative analgesia. *Anesthesiology* 1996; 84:801-806.
23. Ure BM, Spangenberger W, Hebebrand D, et al. Laparoscopic surgery in children and adolescents with suspected appendicitis: results of medical technology assessment. *Eur J Pediatr Surg* 1992; 2:336-340.
24. Tate JJ, Chung SC, Dawson J, et al. Conventional versus laparoscopic surgery for acute appendicitis. *Br J Surg* 1993; 80:761-764.
25. Khalili TM, Hiatt JR, Savar A, et al. Perforated appendicitis is not a contraindication to laparoscopy. *Am Surg* 1999; 65:965-967.