

LIPOMATOUS HAMARTOMA A RARE REASON OF ENDOBRONCHIAL OCCLUSION

Murat Güvener* ❖ Mustafa Yılmaz* ❖ Şanser Ateş** ❖ F. Tanzer Serter* ❖
Murat Özkan* ❖ İlhan Paşaoğlu*

SUMMARY

We reported a case of an endobronchial lipomatous hamartoma which occluded the bronchus of left lower lobe.

Endobronchial lipomatous hamartoma is a very rare benign tumor of the tracheobronchial tree. The medical literature in English by year up to 2000 reported only 56 cases of endobronchial and endotracheal lipoma. Actually, most of them were endobronchial lipomatous hamartomas, there were only a few cases of endobronchial true lipomas published in literature. Differentiation between endobronchial lipomatous hamartomas and endobronchial lipomas has not been made in the literature. This difference change was implied in this case report. Diagnosis and treatment were discussed.

Key Words: Bronchial Occlusion, Endobronchial Lipomatous Hamartoma, Surgical Treatment

ÖZET

Sol Alt Lob Bronşunu Tıkayan Endobronşiyal Lipomatöz Hamartom Vakası

Endobronşiyal lipomatöz hamartom, trakeobronşiyal ağacın nadir görülen, benign bir tümördür. İngilizce literatürde, 2000 yılına kadar bildirilmiş 56 endobronşiyal ya da endotrakeal lipom vardır. Gerçekte, bunların çoğu endobronşiyal lipomatöz hamartomlardır, sadece birkaç gerçek endobronşiyal lipom yayınlanmıştır. Literatürde endobronşiyal lipomatöz hamartom ile gerçek lipomlar arasındaki ayırım yapılmamıştır. Bu çalışmada, bu değişiklik vurgulanmış, tanı ve tedavi yöntemleri tartışılmıştır.

Anahtar Kelimeler: Bronşiyal Oklüzyon, Cerrahi Tedavi, Endobronşiyal Lipomatöz Hamartom, Cerrahi Tedavi

Most tumors of the tracheobronchial tree are malignant in nature. Benign endobronchial tumors are rare and there is considerable confusion regarding the nomenclature and classification. Less than 1% of lung tumors are benign and of these, hamartomas are the most common (1). Endobronchially located hamartomas are rare and account for only 1.4% of all pulmonary hamartomas in a recent analysis (2). Endobronchial hamartomas arise from major bronchi (3). They are composed of mixture of bronchial components (4) and they are described by the principal mesenchymal component (chondromatous, lipomatous or mixed

mesenchymal) (1). Frequently cartilaginous elements predominate in most of them, but a few may contain predominantly adipose tissue or bone. Cytogenetic studies have identified recombinations of chromosomal bands 6p21 and 14q24, supporting the view that hamartomas represent clonal mesenchymal neoplasms (4).

The diagnosis may be suggested by endoscopic aspects, but reliable distinction from a carcinoid or another benign bronchial tumor often is not possible even with biopsies. In the presence of endobronchial lipomatous hamartoma or lipoma, CT may reveal endobronchial tumor with fat density (4).

* Hacettepe University, Faculty of Medicine. Department of Thoracic and Cardiovascular Surgery.

Due to their benign nature, endobronchial lipomas-hamartomas should initially be treated endoscopically. However more frequently endobronchial hamartomas are excised via bronchotomy, another effective and easily performed technique is cryotherapy. Endobronchial laser therapy can also be used (3).

Early endoscopic examination is important for detection of these tumors before the lung distal to the obstruction is irreversibly destroyed. The risk of lung cancer higher in patients with hamartoma than the general population (5). If irreversible lung damage has occurred because of chronic obstruction and suppuration, pulmonary resection may be indicated.

Differentiation of benign endobronchial tumors from malignant lesions are of clinical importance.interest.

CASE REPORT:

A 40-years-old man was admitted to our hospital with a history of productive coughing with expectoration. He has been smoking for 20 years, 1 pack per day. His chest X-rays showed bronchiectatic left lower lobe together with subtotal atelectasis, the CT scan revealed an occlusion in the left lower lobe bronchus. The tumor density could not been discriminated. A well circumscribed, bright yellow tumor with mucosal capillary vessels on surface, moving with respiration and obstructing the bronchus of the left lower lobe was seen by fiberoptic bronchoscopy. Biopsy specimen was not obtained because a punchtaking biopsy from this bronchial tumor that was seen as a vascular mass might cause a bronchial bleeding. Our experience in taking biopsy from vascular tumors by using current bronchoscopic techniques was not appropriate enough. The left lower lobe with its bronchus was resected because the tumor caused to bronchiectasisa and atelectasis. The tumor was considered as malignant rather than benign. Pathological examination revealed exactly the benign characteristics of the lesion. The diagnosis was endobronchial lipomatous hamartoma. Histopathologically, the tumor was consisted predominantly of mature fat cells, a little cartilage and epithelial components. No atypical cells were found (Fig. 1).

One year after the operation, the patient was living his normal life. Control bronchoscopy revealed normal findings without any recurrences.

DISCUSSION:

Endobronchial lipomatous hamartomas are named as endobronchial lipomas by some authors, presence of small quantities of other tissues like cartilage or epithelial components within the lipoma is of little clinical importance. Both are rare benign mesenchymal tumors occuring most commonly in the left main stem bronchus of middle aged male smokers and similar clinical progresses are observed (4). On the other hand, if we classify this tumor as lipoma, we must accept these definitions: 1. They orginate from fatty tissue that is normally present in the tracheobronchial tree, both in the tissue external to the cartilage plates and to a lesser extent in the intersititial tissue of the submucosa (6). 2. They are usually pediculated tumors with a narrow stalks composed of mature fat cells and covered with normal respiratory epithelium. (7,8). 3. True

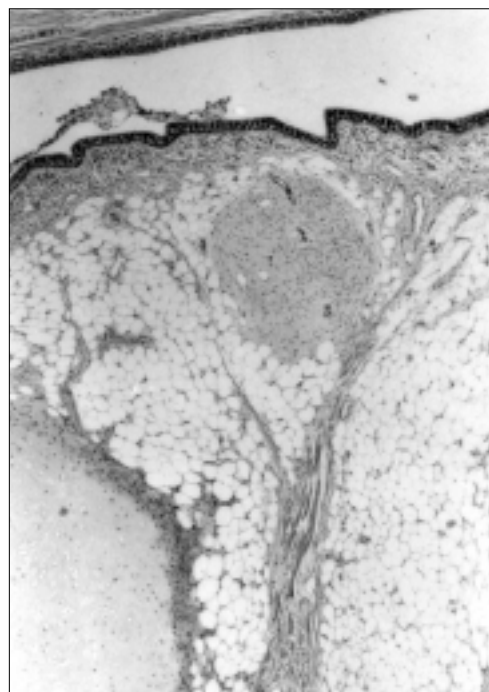


Figure 1: Microscopic section of the endobronchial lipomatous hamartoma. The tumor was consisted predominantly of mature fat cells, a little cartilage, and epithelial components were present. Mature adipose tissue is covered by respiratory epithelium (H. E. stain X100).

lipoma is (encapsulated and consist only of fat cells) in this classification (9). 4. There is no risk of malignant transformation and no risk of recurrence (6-9). As a result, pathologically, “lipoma” is not a proper definition, the tumor is placed in the gray zone (hamartomas) near the lipoma.

The present tumor was defined as an endobronchial lipotamous hamartoma but not as a lipoma. After the histological examination, the tumor was reported to be composed of a little cartilage, predominantly adipose tissue containing mesenchymal tumor, _a hamartoma.

REFERENCES

1. John LCH, Wallis J, Edmondson SJ. Endobronchial chondromatous hamartoma: A rare cause of lobar collapse treated by endoscopic removal. *J Thorac Cardiovasc Surg* 1992; 103: 1226-7.
2. Gjevre JA, Myers JL, Prakash UBS. Pulmonary hamartomas. *Mayo Clin Proc* 1996; 71: 14-20.
3. Şahin AA, Aydiner A, Kalyoncu F, Tokgozoglu I, Barış YI. Endobronchial hamartoma removed by rigid bronchoscope. *Eur Respir J* 1989; 2: 479-80.
4. Stey CA, Vogt P, Russi EW. Endobronchial lipomatous hamartoma; a rare cause of bronchial occlusion. *Chest* 1998; 113: 254-5.
5. Ribet M, Jaillard-Thery S, Nuttens MC. Pulmonary hamartoma and malignancy. *J Thorac Cardiovasc Surg* 1994; 107: 611-4.
6. Doğan R, Ünlü M, Güngen Y, Moldibi B. Endobronchial lipoma. *Thorac Cardiovasc Surgeon* 1988; 36: 241-3.
7. Box K, Kerr KM, Jeffrey R, Douglas JG. Endobronchial lipoma associated with lobar bronchiectasis. *Respiratory Medicine* 1991; 85: 71-2.
8. Pinero A, Gimenez A, Lax FG, Parrilla P. Hemoptysis caused by an endobronchial lipoma. *J Thorac Cardiovasc Surg* 1996; 111: 1104-5.
9. Jensen MS, Petersen AH. Bronchial lipoma. Three cases and review of the literature. *Scand J Thor Cardiovasc Surg* 1970; 4: 131-4.