A. Ü. Vet. Fak. Derg.
35 (2-3) : 396-411, 1988

THE USE OF POLYESTER FIBRE IMPLANTS IN THE TENDON INJURIES OF MARE AND DONKEYS

Erdoğan Samsar[1] **Attila Tanyolaç**[2] **Necdet Güzel**[3]
İ. Ayhan Özkul[4] **Kadircan Özkan**[5] **Perran Gökçe**[6] **Eser Özgencil**[6]

At ve Eşeklerin Tendo Yaralarında Polyester Fibre Implantının Kullanılması

Özet: *Bu çalışmada bir kısrak ve iki eşek kullanıldı. Böylece, bu hayvanların 12 bacağındaki m. flex. dig. supf. ve m. flex. dig. prof. tendolarına operasyon yapıldı. Deneysel olarak kesilen tendolara, Polyester Fibre (Mersilene Mesh "Ethicon") implante edildi.*

En iyi sonuç, m. flex. dig. supf. veya m. flex. dig. prof. tendolarından yalnızca birisine gref uygulandığında elde edildi. M. flex. dig. supf. ve M. flex. dig. prof. tendolarının birlikte operasyona alındığı 2 olguda ise, iyi sonuç alınamadı. Bu olgularda hiperextension görüldü ve tendolar kalınlaşmış olarak kaldı. Yine bu olgularda, implant, minimal bir düzeyde yabancı cisim etkisi yaptı. Uygulanan bandaj, 4-9 hafta arası tutuldu. Sabit bandaj alındıktan sonra, sıkı bir sargı ile bacak desteklendi.

Bu denemelerin sonucunda, hayvanların yürümeleri % 70 oranında iyiydi.

Polyester fibre'ın implantasyonundan sonraki değişik sürelerde alınan tendo materyali, ışık-ve elektron mikroskopunda ayrıca değerlendirildi.

Klinik ve laboratuvar denemelerinin ışığında polyester fibre implantının bir tendo rupturunda başarıyla kullanılabileceği sonucuna varıldı.

Summary: *In this study one mare and two donkeys were used. Also m. flex. dig. supf. or m. flex dig. prof. tendons of 12 limbs of these animals were operated. Polyester Fibre (Mersilene Mesh "Ethicon") implants were used in experimentally injured tendons.*

1 Prof. Dr., AÜ Veteriner Fakültesi, Cerrahi Anabilim Dalı, Ankara.
2 Prof. Dr., AÜ Veteriner Fakültesi Histoloji-Embriyoloji Bilim Dalı, Ankara.
3 Doç. Dr., AÜ Veteriner Fakültesi, Cerrahi Anabilim Dalı, Ankara.
4 Doç. Dr., AÜ Veteriner Fakültesi Patoloji Anabilim Dalı, Ankara.
5 Doç. Dr., SÜ Veteriner Fakültesi, Cerrahi Anabilim Dalı, Konya.
6 Arş. Gör., AÜ Veteriner Fakültesi, Cerrahi Anabilim Dalı, Ankara.

The best result were obtained when only the m. flex. dig. supf. or m. flex. dig. prof. tendon was operated. In two cases, the prognosis was worse, because the m. flex. dig. supf. and m. flex. dig. prof. tendons were operated together. In these cases hyperextension were seen and the tendons have remained thickened. The implant provoked minimal foreign body respons.

Generally, the cast was maintained for 4 to 9 weeks and then replaced with a supporting bandage. At the end of these experiments walking of the animals clinically 70 % were good.

The tendon material was collected at different times after the implantation of polyester fibre and examined under light and electron microscope.

The clinically and laboratory results proved that the polyester fibre could succesfully be used in case of a single tendon.

Introduction

In horses, complete rupture of the flexor digital superficial and profound tendons most frequently involves forelimbs (9). In cattle, the digital flexor tendons of the hindlimbs are most commonly affected, and the gastrocnemius tendon is the 2nd most common site of traumatic rupture (10).

The tendon rupture may involve one or both flexor digital tendons, and in severe cases the suspensory ligament is also involved. The superficial digital flexor tendon usually ruptures just below the carpus or just above the fetlock. The profound digital flexor tendons usually rupture at the level of the sesamoid bone.

The treatment consists of supporting the limb, relieving pain and inflammation and enforcing rest (9).

Experimental studies on donkeys were reported that implants of homografts provide satisfactory substitues for tendons (10).

Auto-grafts have been used to repair the m. gastrocnemius and m. flex. supf. or profound tendons in dogs (Samsar, E. 1974) (11).

In 1976 we learnt of a research project using carbon fibres which had been carried out by D.H.R. Jenkins (2, 5, 7, 8). Part of this study involved the removal of the gastrocnemius tendon from sheep and replacing it with strands of carbon fibre, plaited to from a strong cord which was attached to the tuber calcis and the gastrocnemius muscle.

Jenkins and his colleaques reported that new collagen was deposited along the carbon and a strong and functional "new tendon" was thus formed (7).

The material is reported to provoke minimal foreign body response and to induce the formation of a new tendon like tissue (3).

Further investigation confirmed these findings and showed that this material induced the formation of a tissue closely resembling the original structure (4). These observations aroused interest in the use of carbon fibre for the repair of tendon and ligament injuries in human and animal patients. In horses its value has been tested for the treatment of strains of digital flexor tendons and for tendon severence. Edwards and Vaughon (3), have also used carbon fibre implants to repair the lacerated collateral ligaments of the fetlock joint in horses (3, 12). Authors reported on the experimental replacement of a section of digital with carbon fibre and found that a fibrous structure resembling normal tendon developed around the implant as earyl as 30 days. In their study, a period of 30 days support in a cast was thought adequate; but two horses did show temporary hyperextension of the fetlock. The authors found that when both tendons were severed, support for 90 days was preferable; this is strongly recommended if consistently satisfactory results are to be achieved.

It usually means the replacement of the cast after about 40 days and this also allows inspection of the wound. After removal of the supporting cast a further period of 30 days confinement in a loose box is advisable. Uncontrolled activity at a very earyl stage results in premature overloading of the repair and causes further thickening of the tendon (12).

Filamentous carbon is an expensive material in our country, for this reason we preferably used Polyester Fibre in this study.

Material and Method

In this study one mare and two donkeys were used. Also m. flex. dig. supf. and prof. tendons of 12 limbs of these animals were used.

POLYESTER FIBRE (Mersilene Mesh "Ethicon") implants (Fig. 1) were used in experimentally injured tendons.

Mersilene Polyester Fibre has been used for many years as a suture material. It has also been used in abdominal wall and diaphragmatic defects.



Fig. 1. Photograph of Polyester Fibre sheet.

Mersilene Polyester Fibre Mesh can be cut with scissors to any desired shape depending upon the surgical indications and desires of on experienced surgeon and should be sterilised prior to use by autoclaving at 121 °C for 20 minutes (1).

Polyester Fibre implants were made by folding a piece of Mersilene Mesh sheet like a tendon in shape. They were sterilised in steriliser at 120 °C for 20 minutes.

Mare and donkeys were premedicated with Chlorpromazine (Combelen "Bayer") and Chloralhydrate (8 g/100 kg I. V.). Volar or plantar nerves were anaesthetized with a local anaesthetic solution (Lignocain 2 %).

The region from carpus to hoof (forelimb), from tarsus to hoof (hindlimb) were clipped and thoroughly prepared for an aseptic surgery.

A skin incision was made on the posterior surface of the metacarpus or metatarsus. The m. flex. dig. supf. and m. flex. dig. prof. tendons were exposed. Tenonectomy (5 cm long) were performed on both tendons and 5 cm implants were bridged between the ends of the tendons and sutured to the tendon ends with interrupted sutures of silk (no: 0) (Fig. 2, 3). The skin wound was closed with interrupted sutures with silk (no: 1). A cast of PVC was applied from mid-connon to the hoofs, with foot held in semiflexion to avoid the strain on sutures.

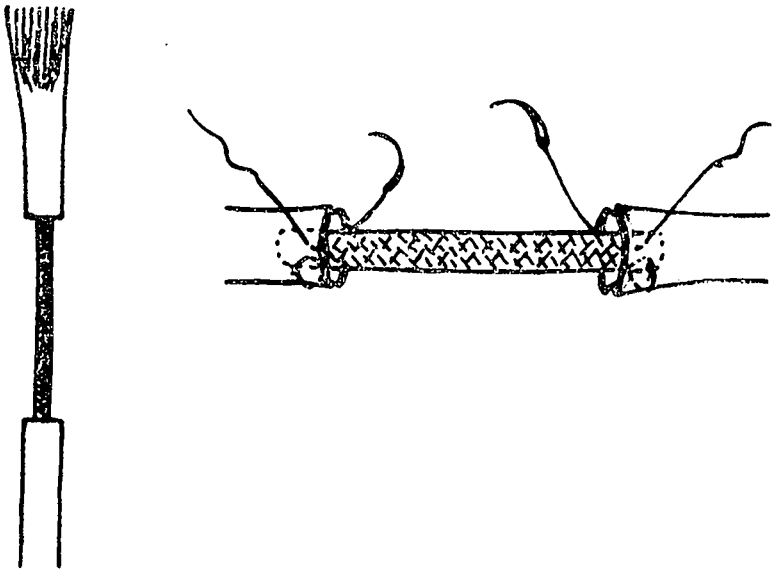

Fig. 2. Diagram showing the method of attaching Polyester Fibre implant between tendon ends.



Fig. 3. Photograph showing the method of attaching implant between tendon ends.

The cast was removed at least after 4–8 weeks and then several weeks of rest in a loose-box was prescribed.

Tissue pieces were taken anaesthetized animals 15 days, 1, 2, 3, 4, 5, 6, 8 and 9 months later operation in order to determine the histopathological tissue formation at the implanted sites. The freeze and paraffin sections were prepared following 10 % formol fixation and dyed with H.E. and trichrom and examined histopathologically under light microscope.

For thin structures the taken pieces were fixed with Karnovsky's method (6) and osmic acid were blocked in Araldit M.

The sections were cut by LKB ultratom III and examined under electron microscope (Carl Zeiss Model EM 9 S–2).

Results

On recovery from anaesthesia the mare and donkeys had no difficulty in walking back to their loose-boxes. The following day, however the lameness was usually worse and some were reluctant to move or to be fed, without medication this discomfort subsided within four to five days. After one week, they took full weight on the operatedleg. In four cases swelling and local heat developed at each incision and also a light discharge of tissue fluid; but this subsided after 7–8 days. In others, antibiotic and Trasylol "Bayer, 25000 KIU" injection was applied locally after the operation. After this application in 8 cases swelling and discharge of tissue fluid was not observed.

In case (Nr. 1) a purulent discharge arouse from the incision. In this case local antibiotic injection was applied for five days. This was succesful. Prompt wound healing then occured, and in this case recovered good function.

In case (Nr. 2), after 5 weeks when the cast of the right hindlimb of the mare was removed the wound been open (5 cm long) and implant which is surrounded by granulation tissue was observed on the incision line. The gap between the cut ends of the tendon had been filled in completelly and there was a little acute inflammation at the operation site. After debridement and irrigation with an antibiotic solution, the wound was closed with interrupted sutures and a rigid suppor ting cast was applied. After 10 days rigid supporting cast was removed, the wound had healed and there was a little swelling at

the operation site. There was not any hyperextension of the digit when the horse had to bear weight.

In case (Nr: 3), after 5 weeks the cast of the left forelimb of the mare was removed. The wound had healed and there was a big swelling at the operation site; and upward tilting of the toe of the hoof when the mare had to bear weight. A new cast was applied for one month. After this time to cast was removed. The implants do not appear to have caused any harm. The mare was generally able to walk; but still there was hyperextension of digit when mare had to bear weight. After 9 weeks the affected tendons were still thickened and local heat was absent. The tendons have remained thickened. The thickness of the affected tendons were twice the normal tendon.

In cases (3, 5), the material provoked minimal foreign body response and it protruded throught the wound. The implant had to be removed because it had protruded throught the wound and produced a little septic discharge.

When the implants ends were throughly buried in the ends of tendon no such complication occured.

The best results were obtained when only the m. flex. dig. supf. or m. flex dig. prof. tendon was operated.

In two cases, the prognosis was worse because the m. flex. dig. supf. and prof. tendons were operated together. In these cases hyperextension were seen and the tendons have remained thickened.

Generally, the cast was maintained for 4 to 9 weeks and then replaced with a supporting bandage. When only one tendon was operated the cast was maintained for 4 weeks; when two tendons were operated in same time the cast was maintained 9 weeks and the best results were obtained.

Three months later from the operation donkeys were ridden at the walk for a similar period and then gradually introduced to a normal programme (life-walking). At the and of this experiments walking of the animals clinically 70 % were good.

Tendons which are operated together hyperextension were seen and the tendons have remained thickened.

Overgrowth of horn most frequent cause of hyperextension for this reason before operation hoof trimming always must be performed.

In general, an acute inflammation and foreign body granulation tissue were observed around the transplanted Mersilene Mesh in all the cases.

15 days after operation: Numerous leucocytes gathered around the foreign body, a few foreign body giant cells formed, fibroblasts surrounded the leucocytes and extended into the leucocyte masses (Fig. 4 and 5).



Fig. 4. 15 daily, M) Mersilene Mesh; L) Leucocytes; arrows) Fibroblasts X 252

1 month after operation: A fibrous capsule, including fibroblasts, was observed around the foreign body (Fig. 5). In the exterior of the capsule found a vast amount of granulation tissue which was dominated also by leucocytes especially lymphocytes. Other than mastocytes, macrophages and, as immune compotent cells, plasmablasts, plasmacytes were found (Fig. 6). These cells found in large numbers in this period were also observed throughout the course of the experiments. The pictures also showed a large number of fibroblasts along with a spread network of capillary vein. Foreign body giant cells were also found at random around the Mersilene Mesh (Fig. 6).

3–4 months after operation: Fibrous capsule became more prominent. A thick layer of fibroblasts and collagen fibres formed and

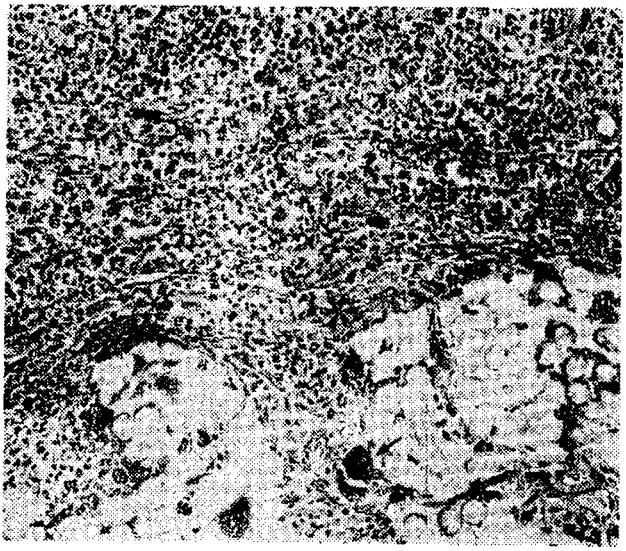

Fig. 5. One monthly, asterisks) Fibrous capsule; arrows) Foreign body giant cells X 160.

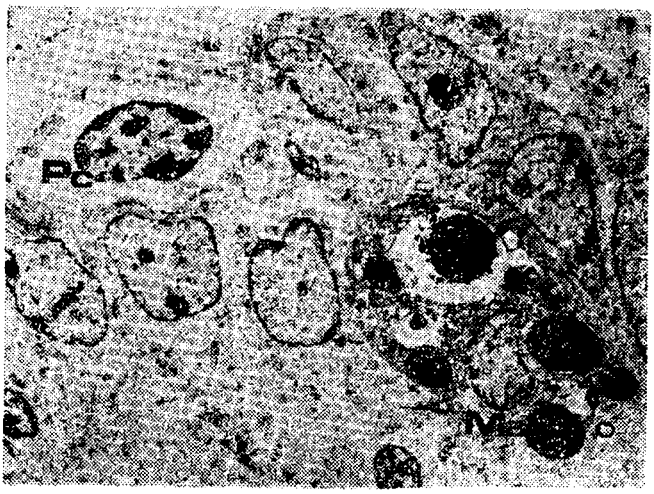

Fig. 6. One monthly, Ma) Macrophage; Pc) Plasma cell X 2400.

Mersilene Mesh clogged by leucocytes, fibroblasts, thin collagen fibres and foreign body giant cells (Fig 9, 10, 11, 14 and 15).

5–6 months after operation: It was observed that fibroblasts found in the fibrous capsule also formed the thick collagen fibre bundles (Fig. 12 arrows).

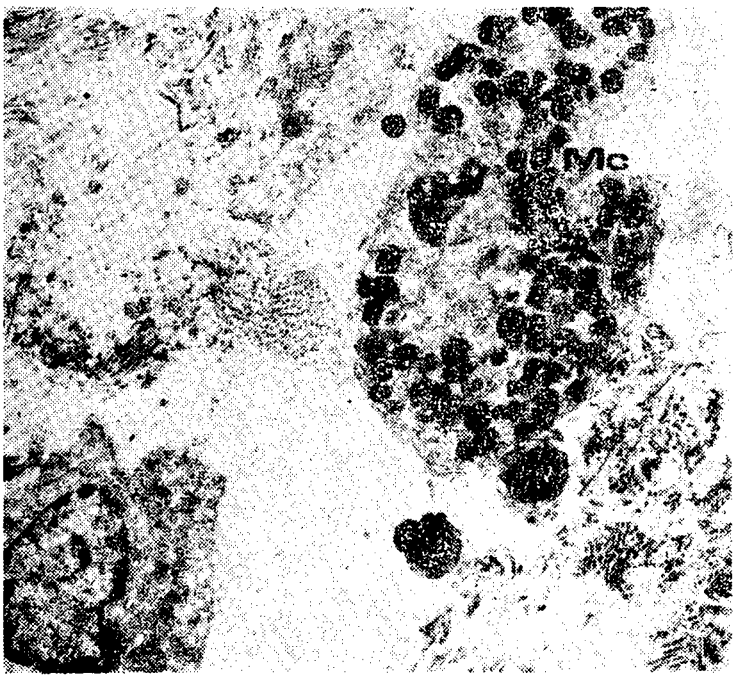

Fig. 7. One monthly, Mc) Mast cell X 7200.

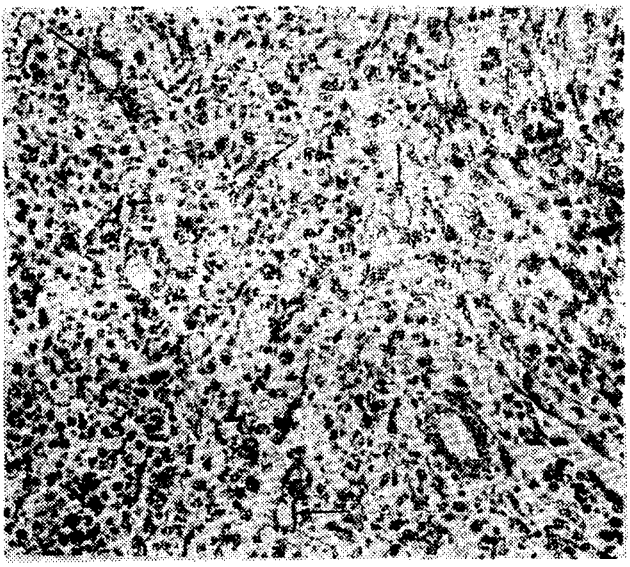

Fig. 8. One monthly, arrows) Numerous young capillaries X 252.

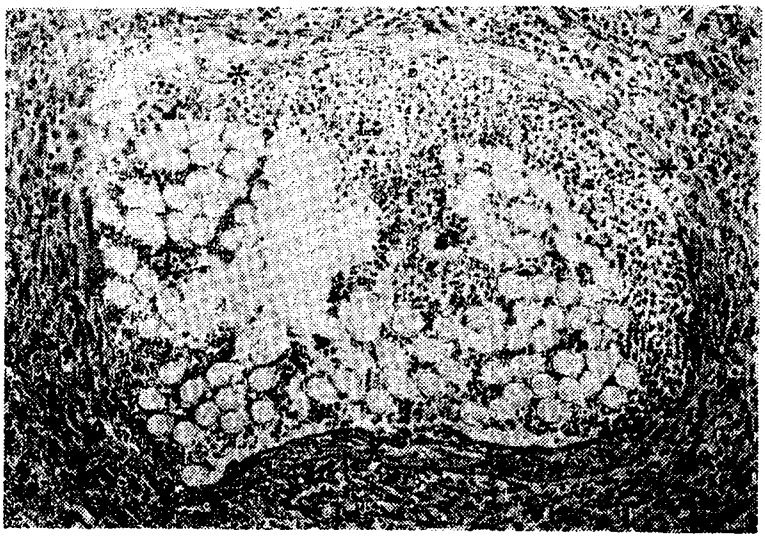

Fig. 9. Three monthly, L) leucocytes; asterisks) Fibrous capsule X 160.

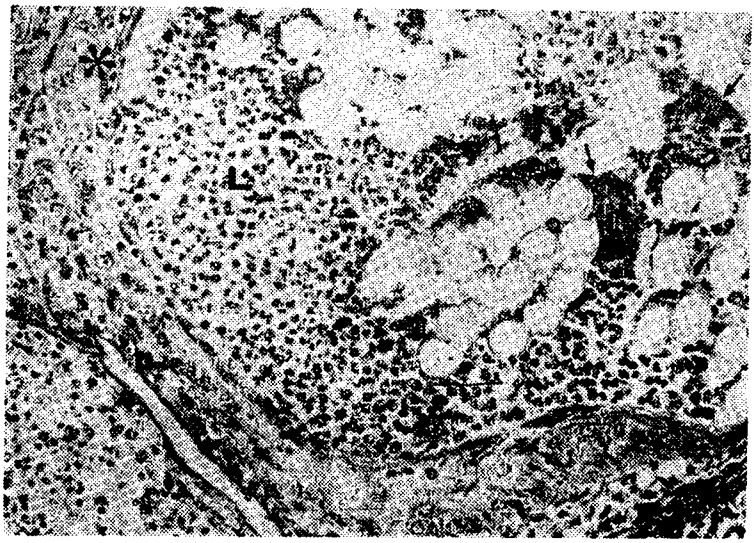

Fig. 10. Three monthly, L) leucocytes; asterisks) Fibrous capsule; arrows) Foriegn body giant cells X 252.

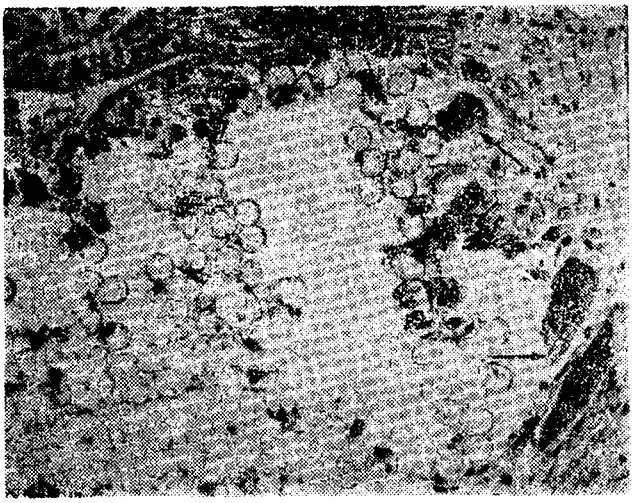

Fig. 11. Four monthly, arrows) Foreign body giant cells X 252.

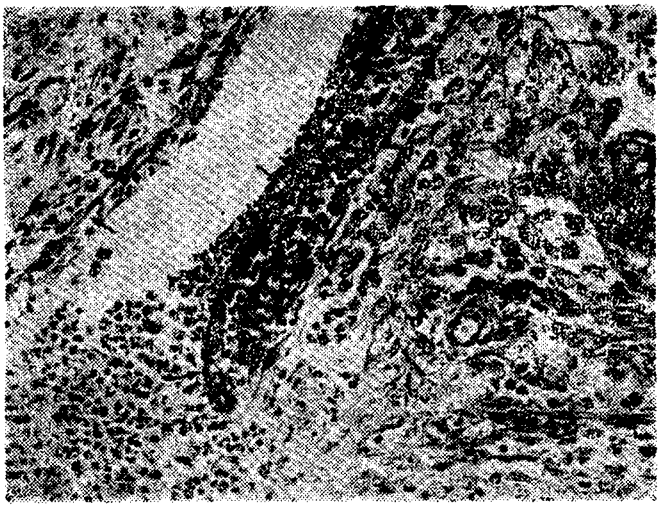

Fig. 12. Six monthly, arrows) Collagen fibres bundles X 252.

8–9 months after operation: It was seen that the thinner fibres leaving the thick collagen fibre bundles wrapped the meshed tissue of the implant (Fig. 13).

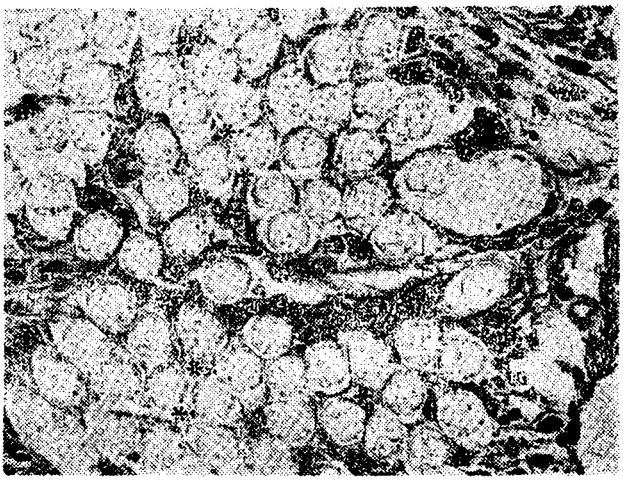

Fig. 13. Eight monthly, asterisks) Collagen fibres which are spred to the pores of the foreign material X 400.

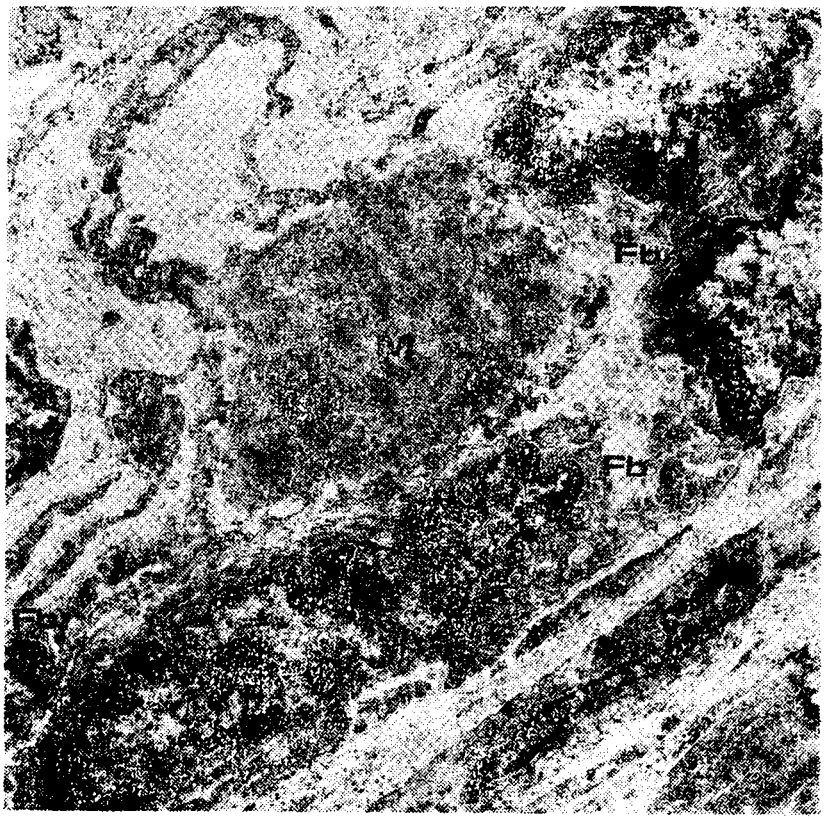

Fig. 14. Collection of fibroblasts (Fb) around the Mersilene Mesh (M) during the early period following operation X 9000.

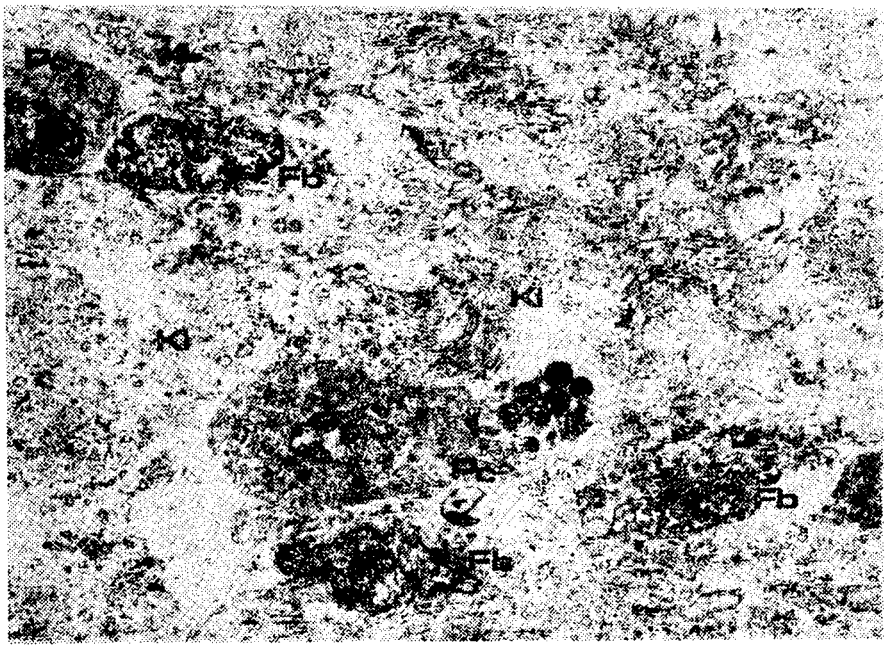

Fig. 15. Fibrous tissue elements frequently observed in the operation area as one monthly period, Fb) Fibroblasts; Kl) Collagen fibres; Pc) Plasma cells X 3600.

Discussion and Conclusion

Samsar, E. (10) reported the successful use homograft in the repair of tendon, and in 1974 also Samsar, E. (11) reported the successful use of autograft in the repair of tendon.

In 1977–1978 Jenkins and others (2, 5, 7, 8) report that implant of filamentous carbon provided satisfactory substitutes for ligaments and tendons in experimental sheep and rabbits stimulated its use for the reconstruction of these structures clinically in men and animals. The material is reported to provoke minimal foreign body response and to induce the formation of a new tendon like tissue (3).

In our experiments Polyester Fibre implants were used. The prognosis was good in case of m. flex. dig. supf. or prof. The best results were achived when only one tendon was operated; but when two tendons were operated together poor results were obtained. Also the ten-

Table 1. Results of Treatment in Mare

Case Nr.	Operated tendon	Time of treament and cast	Sequel
1	MFS (RF)	5 weeks	Walked successfully
2	MFS (RH)	5 weeks-10 days	Walked successfully
3	MFS-MFP (LF)	5 weeks-4 weeks	Hyperextension
4	MFP (LH)	5 weeks	Walked successfully

Table 2. Results of Treatment in Donkeys

Case Nr.	Operated tendon	Time of treament and cast	Sequel
5	MFS-MFP (RF)	5 weeks	Thickened tendon and hyperextension
6	MFS-MFP (RF)	5 weeks	Thickened tendon and hyperextension
7	MFP (RH)	4 weeks	Walked successfully
8	MFP (RH)	4 weeks	Walked successfully
9	MFP (LH)	4 weeks	Walked successfully
10	MFS (LF)	4 weeks	Walked successfully
11	MFS (LH)	2 weeks-3 days	Euthanasia
12	MFP (LF)	2 weeks-3 days	Euthanasia

MFS: M. flex. dig. supf.
MFP: M. flex. dig. prof.
RF: Right forelimb
RH: Right hindlimb
LF: Left forelimb
LH: Left hindlimb

dons have remained thickened and the implants caused minimal foreign body reactions. However the Polyester Fibre implants can be used in single tendon ruptur.

Our results on formation of capsule around Mersilene-Mesh by fibroblasts, reinforcement of capsule by collagen fibres and clogging of thinner collagen fibres the mesh tissue of the implant resemble the findings of Goodship and Brown (5). In this work, the finding of cells with picnotic nuclei among leucocytes and lymphocytes shows the destruction of immune reaction or the phagocytosis period. Our results, however, conflict with Goodship and Brown (5) in that they

did not observe any inflammation and found a very few foreign body giant cells in their work on the achil tendon of California rabbit they implanted "carbon fibre". As a result it can be said that the low price and high success in curing make Mersilene-Mesh an accaptable implant.

References

1. **Anteplioğlu, H., Samsar, E.** (1976): *Büyükbaş Ruminatlarda Geniş Defektli Fıtık Deliklerinin Sentetik Greflerle Onarılması.* AÜ Vet. Fak. Derg. 23, (1–2): 89–102.
2. **Bredin, K.** (1986): *Treatment of a Strained Tendon in a Thorughbred Racehorse with Carbon Fibre Filaments.* Irish Veterinary Journal 40: 139–140.
3. **Edwards, G.B., Vaughan, L.C.** (1984): *Use of Carbon Fibre Implants in the Treatment of Fetlock Joint Dislocation in Two Horses.* Veterinary Record 114, (Jan. 28): 87–88.
4. **Forster, L.W., Ralis, Z.A., Mc Kibbin, B., Jenkins, D.H.R.** (1978): *Biological Reaction to Carbon Fibre Implants. The Formation and Structure of a Carbon-Induced "Neotendon"* Clin. Orthop. 131: 299–307.
5. **Goodship, A.E., Brown, P.N., Jenkins, D.H.R., Silver, L.A.** (1980): *An Assesment of Filamentous Carbon Fibre for Treatment of Tendon Injury in the Horse.* Veterinary Record 106, (March 8): 217–221.
6. **Karnovsky, M.J.** (1965): *A Formaldehyde-glutaraldehyde Fixative of High Osmolality for Use in Electron Microscopy.* J. Cell Biol., 27: 137 A–138 A.
7. **Little Wood, H.F.** (1979): *Treatment of Sprained Tendons in Horses with Carbon Fibre Implants.* Veterinary Record. 105, (Sept. 8): 223–224.
8. **Mc Gill, C.A., Fraser, D.M.** (1983): *The Use of Carbon Fibre İmplants to Repair Severed Digital Flexor Tendons in a Fallow Deer.* Australian Veterinary Journal 60, (10): 318.
9. **Oehme, F.W., Prier, J.E.** (1975): *Large Animal Surgery. The Williams and* Wilkins Company. Baltimore.
10. **Samsar, E.** (1973): *At ve Merkeplerin Metacarpus ve Metatarsus Bölgelerindeki M. flex. dig. supf. ve prof. Tendolarında Dikiş ve Homogref Uygulamaları Üzerinde Deneysel Çalışmalar.* AÜ Vet. Fak. Derg. 20, (1): 14–34.
11. **Samsar, E.** (1974): *Köpeklerde Deneysel Tendo Dikişleri ve Tendo Autogrefleri.* AÜ Vet. Fak. Derg. 21, (1–2): 70–79.
12. **Valdez, H., Coy, H.C., Swanson, T.** (1982): *Flexible Carbon Fibre for Repair of Gastrocnemius and Superficial Digital Flexor Tendons in a Heifer and Gastrocnemius Tendon in a Foal.* JAVMA-181, (2): 154–157.