

# The Effect of Removable Partial Dentures on Alveolar Bone Resorption: A Retrospective Study with Cone-Beam Computed Tomography

Oguz Ozan, PhD,<sup>1</sup> Kaan Orhan, PhD,<sup>2,3</sup> Secil Aksoy, DDS,<sup>3</sup> Murat Icen, DDS,<sup>3</sup> Burak Bilecenoglu, PhD,<sup>4</sup> & Bayram Ufuk Sakul, PhD<sup>4</sup>

<sup>1</sup>Department of Prosthodontics, Near East University, Faculty of Dentistry, Mersin 10, Turkey

<sup>2</sup>Department of Dentomaxillofacial Radiology, University of Ankara, Faculty of Dentistry, Ankara, Turkey

<sup>3</sup>Department of Dentomaxillofacial Radiology, Near East University, Faculty of Dentistry, Mersin 10, Turkey

<sup>4</sup>Department of Anatomy, University of Ankara, Faculty of Dentistry, Ankara, Turkey

## Keywords

Cone-beam computed tomography; removable partial denture; alveolar bone resorption; edentulous arch.

## Correspondence

Oguz Ozan, Department of Prosthodontics, Near East University Faculty of Dentistry, Mersin 10/Lefkosa, Turkey. E-mail: oguzozan@gmail.com.

*The authors deny any conflicts of interest.*

Accepted March 7, 2012

doi: 10.1111/j.1532-849X.2012.00877.x

## Abstract

**Purpose:** The aim of this study was to compare vertical and horizontal mandibular alveolar bone resorption by measuring bone morphological variation in Kennedy Class II removable partial denture (RPD) wearers and non-wearers using cone-beam computed tomography (CBCT).

**Materials and Methods:** In total, 124 sites in the CBCT scans of 62 (29 RPD non-wearers, 33 RPD wearers) Kennedy Class II patients were analyzed retrospectively. Three-dimensional representations of the mandible with superimposed cross-sectional slices were developed with the CBCT scans to evaluate the mandibular alveolar height and width by measuring distances between the mandibular canal, mylohyoid ridge, alveolar crest, and lower border of the mandible in four regions (eight sites) of Kennedy Class II non-wearers and wearers of RPDs.

**Results:** Mandibular alveolar bone height and width were significantly lower in edentulous sites when compared with dentate sites in both Kennedy Class II non-wearers and wearers of RPDs ( $p < 0.05$ ). Additionally, mean vertical and horizontal mandibular bone resorption was significantly higher in RPD wearers than in non-wearers ( $p < 0.05$ ).

**Conclusions:** Vertical and horizontal alveolar bone resorption was found to be higher in the RPD wearing patients when comparing the dentate and edentulous sites.

Improving quality of life by restoring function and esthetics is a major goal in the rehabilitation of removable denture users, especially elderly patients. Gender, genetics, systemic conditions, tooth loss sequence, duration of edentulism, and other unknown factors influence the chronic remodeling/resorption process of the edentulous jaw.<sup>1-5</sup> Gross resorption of the edentulous mandibular alveolar process, resulting in excessive loss of the denture-bearing ridge, is a commonly encountered problem in the prosthetic rehabilitation of elderly patients.<sup>6</sup> Such ridge resorption can vary among individuals, between and within jaws, and over time.<sup>7</sup>

Previous researchers have stated that removable partial denture (RPD) wear and pressure, represented in terms of time and denture use, can be factors underlying residual ridge resorption.<sup>1,2,4,8</sup> Merrot et al<sup>9</sup> pointed out that the loss of teeth considerably modifies not only the shape of the mandibular alveolus, but also the mandibular base. Chrcanovic et al<sup>10</sup> also stated that

the presence or absence of teeth can alter the mandibular shape and that mandibular edentulism may be associated with specific changes in the mandible. Most studies have concluded that alveolar resorption occurs vertically,<sup>2,7-9</sup> but few studies have examined horizontal resorption in the mandible.<sup>3,4</sup> Researchers have also observed that the basal area of the mandible is the major site of bone loss under dentures.<sup>1,3,7,8,11</sup>

The significance of disuse atrophy of edentulous jaws has often been suggested, indicating that good-quality dentures should prevent residual ridge resorption, whereas lack of dentures would be expected to lead to increased bone loss; however, this concept was questioned in the 1960s, leading to the new idea that denture-bearing jaws lost more bone than those without dentures.<sup>4,12,13</sup> Such inconclusive results are often seen in the literature on denture-related bone resorption.<sup>4</sup> Whether mucosa- and/or tooth-supported RPD use is associated with residual ridge resorption has not yet been clarified.

Thus, it was considered worthwhile to evaluate and compare vertical and horizontal mandibular alveolar bone resorption by measuring bone morphological variation in Kennedy Class II RPD wearers and non-wearers using cone-beam computed tomography (CBCT) imaging.

## Material and methods

In total, 124 sites in the mandibles of 62 participants (35 men, 27 women), ranging in age from 42 to 76 years, who had craniofacial CBCT scans, were investigated retrospectively. All patients had Kennedy Class II edentulism. Of the patients, 29 (17 men, 12 women) were RPD non-wearers and 33 (18 men, 15 women) were RPD wearers.

According to previous studies<sup>6,14</sup> edentulous areas in the mandible usually do not undergo severe atrophy during a period of <5 years. Thus, this study included only patients with a history of  $\geq 5$  years since extraction and, in RPD wearers,  $\geq 5$  years of RPD use. Patients with evidence of bone disease, especially osteoporosis, and related drug consumption, skeletal asymmetries, or trauma were excluded.

The age range of the RPD wearers was 55 to 76 years (mean 59.7) and that of the RPD non-wearers was 42 to 61 years (mean 52.2). The retrospectively evaluated CBCT images were taken for pre-implant imaging.

This study was based on the retrospective evaluation of radiographs. Thus, no ethical approval was necessary from the local ethical committee because only archived data were used; however, before taking any radiograph or performing any intra-/extraoral examination, patients gave informed consent according to the principles of the Helsinki Declaration, including all amendments and revisions. The informed consent forms were reviewed and approved by the institutional review board of the faculty.

Collected data were accessible only to the researchers. Moreover, the observers only examined the radiographs and were blinded to any other patient data in the radiographic examination procedure. No preferences were made regarding gender in sample choice. Only high-quality scans were included. Low-quality images, such as those with scattering or insufficient accuracy of bony border visualization, were excluded.

A NewTom 3G (Quantitative Radiology s.r.l., Verona, Italy) was used to make CBCT scan. A 9-inch field of view included

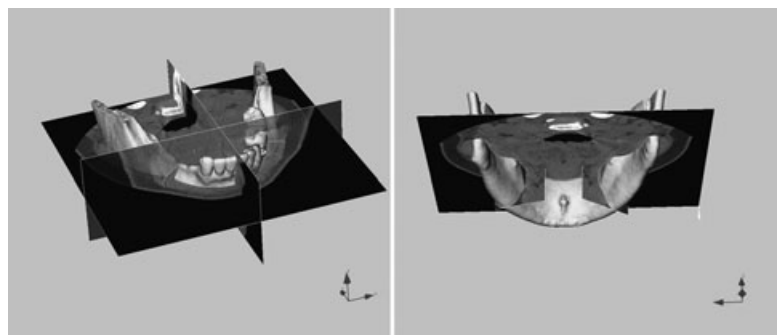
the mandibular and maxillary anatomy. X-ray parameters (kV, mA) were automatically determined from scout views by the NewTom 3G. Variation in exposure of up to 40% was possible, depending on the size of the patient and the extent of beam attenuation.

An 0.3-mm axial slice thickness was used, and the voxels were isotropic. The axial images were exported as a  $512 \times 512$  matrix in DICOM file format. They were then imported with Maxilim software (ver. 2.3.0; Medicim, Mechelen, Belgium). All constructions and measurements were performed on a 21.3-inch flat panel color active matrix TFT medical display (Nio Color 3MP; Barco, Kortrijk, Belgium) with a resolution of  $2048 \times 1536$  at 76 Hz and 0.2115 mm dot pitch, operated at 10 bit. A maxillofacial radiologist (KO) and a prosthodontist (OO) who are experienced in 3D segmentation and evaluation made high-quality 3D hard-tissue surface representations, computed from the patients' CBCT dataset in several stages, and examined all images.

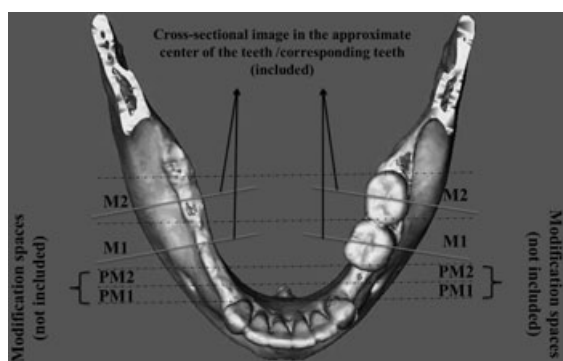
Bone and soft-tissue surfaces were segmented by applying a threshold on the acquired image volume of radiographic densities. Noise reduction was attempted without reducing actual osseous anatomy. To begin the analysis, the segmented hard surface representations of the skull were virtually rendered. After semi-automated virtual standardized positioning of the skull, high-quality 3D hard-tissue surface representations were computed from the patients' CBCT dataset. The axial and cross-sectional CT radiographic slices were superimposed over reconstructed 3D images (Fig 1). Measurements of the 3D images were made on the 3D surface-rendered volumetric image with superimposed cross-sectional slices using rotation and translation of the rendered images. Landmarks were identified using a cursor-driven pointer.

First, eight mandibular areas in four regions of each patient were identified and characterized according to edentulism (edentulous or dentate): the regions were the first premolar (PM1), second premolar (PM2), first molar (M1), and second molar (M2) regions. The modification spaces and corresponding edentulous areas in the mandibular premolar and molar regions of Kennedy Class II patients were excluded (Fig 2).

To evaluate the dentate areas, 3D superimposed cross sections were taken from the center of the teeth. Measurements were made in the approximate center of the teeth on this image.



**Figure 1** 3D image generated from volumetric rendering software with axial and cross-sectional CT radiographic slices, which were superimposed over reconstructed 3D images.



**Figure 2** First premolar (PM1), second premolar (PM2), first molar (M1), and second molar (M2) measurement areas. The modification spaces and corresponding edentulous areas in the mandibular premolar and molar regions of Kennedy Class II patients were excluded.

To evaluate the edentulous regions, a plane was drawn perpendicular to the mandibular plane in the approximate center of the corresponding teeth on the same 3D image. Measurements were then performed from this superimposed cross-sectional image of the corresponding edentulous site (Fig 2).

In total, 2238 measurements (1080 in RPD non-wearers, 1158 in RPD wearers) were made. Measurements were taken between the nearest point of the mandibular canal (MC) and the mylohyoid ridge (MR), between the alveolar crest (Crest) and the MR, between the MC and Crest, and between the MC and the lower border of the mandible (LBM; Fig 3). The total height of the mandibular alveolar bone was also measured between the Crest and LBM, while the width of the mandible was measured from the level of the MR in dentate and edentulous sites in RPD wearers and non-wearers (Fig 4). Additionally, the total percentage of alveolar bone loss for each site was calculated as the ratio of dentate to edentulous site measurements in RPD wearers and non-wearers. The percentages of horizontal and vertical alveolar bone loss were then compared statistically between RPD wearers and non-wearers.

All measurements were taken twice by the observers, and the mean of these measurements was recorded. The observers also performed the study twice at an interval of 2 weeks to assess inter- and intraobserver variability.

### Statistical methods

Statistical analyses were carried out using SPSS software (ver. 12.0.1; SPSS Inc., Chicago, IL). Intraobserver reliability was assessed by calculating intraclass correlation coefficients (ICCs) for observers' repeated measurements, and interobserver reliability was assessed using the Wilcoxon matched-pairs signed-ranks test. Pearson chi-squared tests and Student's *t*-tests were used for statistical analyses of gender and dentate and edentulous sites of RPD wearers and non-wearers, and *p* values < 0.05 were considered statistically significant.

## Results

### Methodological error

Overall intraobserver reproducibility was 0.93 to 0.99 for observer 1 and 0.98 to 0.99 for observer 2, indicating nearly perfect reproducibility. Repeated measurement of CBCTs also yielded no significant interobserver difference ( $p > 0.05$ ). Interobserver consistency was rated at 95.7% between the two observers.

The MC to MR, Crest to MR, Crest to MC, and MC to LBM measurements for RPD wearers and non-wearers (edentate and dentate sites) are presented in Table 1. Overall, the total mean values for each measurement except MC to LBM were significantly lower at edentulous sites than at dentate sites in both RPD wearers and non-wearers ( $p < 0.05$ ). When RPD wearers and non-wearers were compared, the total mean differences (%) between dentate and edentulous sites were statistically significant ( $p < 0.05$ ) for the MC to MR, Crest to MR, and Crest to MC measurements, whereas the MC to LBM measurement showed no significant difference ( $p > 0.05$ ). In a comparison by region, mean differences (%) in MC to MR measurements between edentulous and dentate sites were significantly smaller at PM2 (20.4%) than at M2 (26.5%) ( $p < 0.05$ ), which was in line with Crest to MR measurements at PM1 (15.1%) than at M1 (18.6%) in RPD wearers ( $p < 0.05$ ; Table 1).

Table 2 presents the alveolar height and width measurements according to dentate and edentulous sites in RPD wearers and non-wearers. The width and height of the mandible were significantly smaller at edentulous sites than at dentate sites. The mean differences (%) in alveolar height and width differed significantly ( $p < 0.05$ ) between RPD wearers and non-wearers at both dentate and edentulous sites.

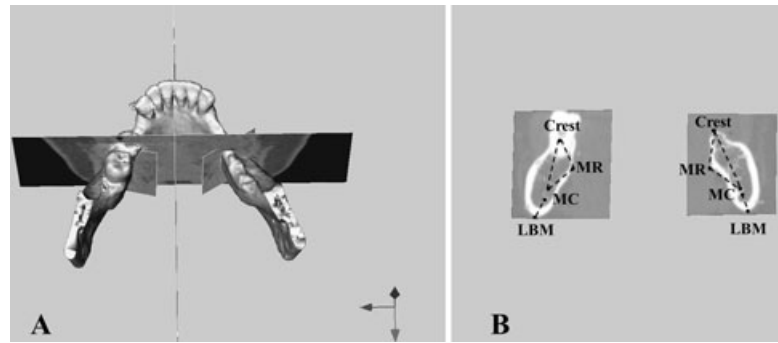
The mean differences in alveolar height were 22.7% in RPD non-wearers and 28.8% in RPD wearers, and the mean differences in alveolar width were 9.1% and 14.5%, respectively. In a comparison by region, the mean difference (%) between edentulous and dentate site measurements of alveolar height was significantly greater at PM1 (25.4%) than at PM2 (20.9%) in RPD non-wearers ( $p < 0.05$ ), whereas the difference in alveolar width from MR was significantly lower at PM1 (12.3%) than at M2 (15.7%) in RPD wearers ( $p < 0.05$ ; Table 2).

### Discussion

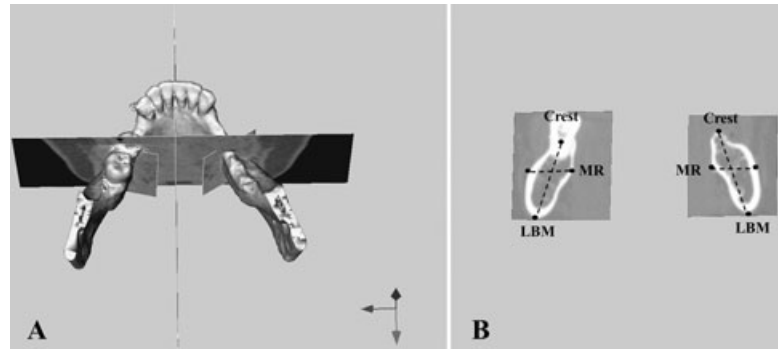
Previous studies have indicated that alveolar bone resorption begins immediately following the loss of a tooth and continues in an accelerated manner for about 10 weeks, followed by slower, but progressive, resorption thereafter.<sup>7</sup> The best approach to prevent this resorption is to preserve the residual alveolar ridge using different kinds of prosthetic rehabilitation. Carlsson<sup>4</sup> stated in a review that the best way to manage bone resorption was to avoid tooth extraction, preserving a few teeth in the mouth. The use of tooth-supported dentures also appeared to slow the resorption process.<sup>15</sup> Moreover, numerous studies have indicated that the morphology of the mandible is preserved or changes with the presence or absence of teeth in elderly populations.<sup>1,2,6,9,10</sup>

Petrokovski et al<sup>1</sup> examined the morphology of the retro-molar area in edentulous dry mandibles and compared the bone

**Figure 3** (A) To evaluate the dentate/edentulous regions, 3D superimposed cross sections were taken for each site. (B) Measurements were taken between the nearest point of the MC and the mylohyoid ridge (MR), between the alveolar crest (Crest) and the MR, between the MC and the Crest, and between the MC and the LBM.



**Figure 4** (A) To evaluate the dentate/edentate regions, 3D superimposed cross sections were taken for each site. (B) The total height of the mandibular alveolar bone was measured between the alveolar crest (Crest) and the LBM, and the width of the mandible was measured from the level of the MR.



loss with that in dentate dry mandibles. They demonstrated that the distance from the edentulous crest to the MR was decreased markedly in the edentulous group. Similarly, Merrot *et al*<sup>9</sup> studied dentate and edentulous mandibles of elderly individuals to define the characteristics of edentulous mandibles. They concluded that the loss of teeth considerably modified the shape not only of the mandibular alveolus, but also the mandibular base. The authors of another study<sup>10</sup> used dry mandibles to evaluate bone resorption in dentate and edentulous subjects, and concluded that loss of teeth can alter the mandibular shape. In a recent study, Canger and Celenk<sup>16</sup> radiographically examined on panoramic images the effects of denture use on alveolar ridge height. They found that reduction in residual alveolar ridge height was closely related to edentulism and denture use. Similarly, Pietroskivski *et al*<sup>3</sup> stated that denture non-users tended to have more residual edentulous tissue compared with denture users.

In this study, both RPD wearers and non-wearers showed a tendency for bone resorption, as assessed by the measurement of mandibular height and width, in edentulous sites compared with dentate sites; this finding is consistent with those of previous studies.<sup>2,3,6,7</sup> However, all previous studies investigated bone resorption by comparing dentate/edentate groups and denture users/non-users in different participants or specimens (dry mandibles). Before this study, no attempt had been made to evaluate bone resorption in dentate and edentulous areas in the same patient. In our study, we compared not only denture users and non-users, but also ridge resorption in dentate and edentulous areas in the same patient. In our opinion, this approach should be used in further studies to enable the standardization of study groups for evaluating and understanding the mechanism

of alveolar ridge resorption. It was also concluded that ridge resorption can vary among individuals, between and within jaws, and over time.<sup>7</sup> Time, denture experience, and other unknown factors may affect the reduction of denture-supporting edentulous tissues.<sup>3</sup> In our opinion, to understand alveolar bone resorption, these unknown factors, which may vary among patients, should be eliminated as much as possible by examining dentate and edentulous sites in the same patient.

A previous study<sup>6</sup> found that the mandibular resorption rate was greatest in the early stages of edentulism and slowed as the edentulous period continued. The same study showed a mean loss of 23.09% of mandibular height during the first 5-year period of edentulism; in the next 5 to 10 years, the mean ridge reduction was 26.05%; and in the next 10-plus years, this increased an additional 5.61%, for a total loss of 28.70% in denture-wearing patients.

This study included only patients with a history of  $\geq 5$  years since extraction and, in RPD wearers,  $\geq 5$  years of RPD use. The results showed mean losses of 22.7% and 28.8% for RPD non-wearers and wearers, respectively; this degree of vertical bone resorption is similar to that found in a previous study.<sup>6</sup> Moreover, the alveolar height in this study was measured not only from the LBM to the alveolar crest, but also from the crest to MR and MC. These measurements demonstrated more mandibular resorption in RPD wearers than in non-wearers when comparing dentate and edentulous areas.

Similar results have been reported previously. Mori *et al*<sup>17</sup> conducted a study in rats and found that the lowest pressure on the rat jawbone caused no bone resorption, but higher pressure lead to increased bone resorption. Reddy *et al*<sup>18</sup> also stated that dentures do not provide adequate functional stimulation to the

**Table 1** Measurements from the MC to the mylohyoid ridge (MR), alveolar crest (Crest) to the MR, Crest-MC, and MC to the LBM at dentate and edentulous sites in four mandibular tooth regions (PM1, PM2, M1, M2) in RPD wearers and non-wearers. Superscripted letters indicate statistically significant differences ( $p < 0.05$ ) between values with the same letter

Region	MC-MR				Crest-MR				Crest-MC				MC-LBM			
	Dentate (mm ± SD)	Edentulous (mm ± SD)	Mean difference (%)		Dentate (mm ± SD)	Edentulous (mm ± SD)	Mean difference (%)		Dentate (mm ± SD)	Edentulous (mm ± SD)	Mean difference (%)		Dentate (mm ± SD)	Edentulous (mm ± SD)	Mean difference (%)	
RPD non-wearers	PM1	9.3 ± 1.2	7.8 ± 1.6	16.1	17.4 ± 1.5	15.4 ± 1.4	11.5		14.2 ± 1.5	11.4 ± 1.5	19.7		9.7 ± 1.4	9.6 ± 1.2		
	PM2	9.4 ± 1.4	7.8 ± 1.4	17.1	18.1 ± 1.2	15.7 ± 1.1	13.2		13.9 ± 1.6	11.2 ± 1.6	19.4		10 ± 1.3	9.7 ± 1.3		
	M1	10.1 ± 1.2	8.3 ± 1.3	17.8	17.2 ± 1.4	15.1 ± 1.4	11.9		13.6 ± 1.4	10.9 ± 1.4	18.3		9.6 ± 1.2	9.8 ± 1.5		
	M2	10.4 ± 1.4	8.4 ± 1.7	18.2	18.4 ± 1.7	15.7 ± 1.6	13.5		13.7 ± 1.5	10.9 ± 1.5	18.9		9.4 ± 1.1	9.7 ± 1.3		
Total mean	9.8 ± 1.3	8 ± 1.5	<b>17.3<sup>a</sup></b>	17.8 ± 1.4	15.5 ± 1.3	<b>12.5<sup>c</sup></b>		13.8 ± 1.6	11.1 ± 1.6	<b>19.1<sup>g</sup></b>		9.6 ± 1.2	9.7 ± 1.4			
RPD wearers	PM1	9.5 ± 1.1	7.4 ± 2.7	22.1	17.2 ± 1.3	14.6 ± 1.2	<b>15.1<sup>d</sup></b>		14.0 ± 1.3	10.5 ± 1.1	23.3		9.6 ± 1.2	9.4 ± 1.1		
	PM2	9.3 ± 1.5	7.4 ± 1.4	<b>20.4<sup>b</sup></b>	17.4 ± 1.2	14.4 ± 1.2	17.2		13.8 ± 1.5	10.4 ± 1.0	24.6		9.8 ± 1.4	9.5 ± 1.2		
	M1	9.6 ± 1.3	7.7 ± 1.7	22.2	17.2 ± 1.1	14.0 ± 1.1	<b>18.6<sup>d</sup></b>		13.6 ± 1.2	10.3 ± 1.2	24.2		9.7 ± 1.2	9.6 ± 1.4		
	M2	9.8 ± 1.4	7.2 ± 1.3	<b>26.5<sup>b</sup></b>	17.1 ± 1.3	14.5 ± 1.4	15.2		13.4 ± 1.4	10.4 ± 1.4	22.3		9.6 ± 1.3	9.7 ± 1.5		
Total mean	9.5 ± 1.6	7.4 ± 1.7	<b>22.8<sup>a</sup></b>	17.2 ± 1.2	14.4 ± 1.2	<b>16.5<sup>c</sup></b>		13.7 ± 1.4	10.4 ± 1.2	<b>23.6<sup>g</sup></b>		9.6 ± 1.3	9.5 ± 1.4			

bone. Thus, functional stimulation can induce alveolar bone resorption rather than preserving the edentulous area, and may be as important as pressure caused by dentures. In our opinion, the pressure exerted by RPDs in the edentulous regions of the alveolar bone may increase resorption in RPD wearers when compared with non-wearers.

Previous studies have shown that denture wearers have smaller arches and ridges than non-wearers.<sup>3,8,10</sup> Although almost all studies have agreed that alveolar bone height is reduced with the use of removable dentures,<sup>3,6,13,19</sup> the effect of RPDs on the MR horizontally has not been investigated in detail. The anatomy of the MR and surrounding structures is crucial for prosthetic treatment planning. Bone resorption in the MR region can affect the success of prosthetic applications, and the removable denture base should cover the MR region to provide proper basal sealing and denture function.<sup>1</sup> In this study, we investigated horizontal bone resorption from the level of the MR by comparing the alveolar width from the MR to the MC and the alveolar crest at edentulous and dentate sites in RPD wearers and non-wearers. Horizontal bone resorption was higher in RPD wearers than in non-wearers. This finding can be interpreted as the effect of RPDs covering the MR area and reducing muscle activation under the denture, which is supported by some previous studies.<sup>1,11</sup> Koshino et al<sup>11</sup> suggested that the basal area of the removable denture foundation greatly influenced masticatory efficiency. Moreover, Petrokovski et al<sup>1</sup> stated that the mylohyoid muscle attached to bony MRs, the buccinator muscles attached to the bony buccal shelves, and the additional muscles that surround the mandible are among the factors that limit chronic bone resorption in the edentulous jaw. These muscles provide physiological stimulation of the edentulous area and thus prevent bone resorption, as noted in previous reports.<sup>20,21</sup> In our opinion, the increased horizontal bone resorption in RPD wearers may be due to the RPD's covering of the basal area, which limits masticatory efficiency.

Previous studies have found that bone resorption is correlated with reduced muscle activity. Ausk et al<sup>22</sup> investigated cortical bone resorption in mice and found that transient muscle paralysis or inactivation led to spatially consistent cortical resorption. In another animal study,<sup>23</sup> researchers paralyzed the muscle unilaterally using Botox and investigated the effects of muscle paralysis on bone resorption compared with the control contralateral unaffected muscle and bone. They observed that the paralyzed muscle side showed bone degradation, which can be explained by a decisive role of muscle contraction in maintaining bone mass. Sakata et al<sup>24</sup> stated that bone loss due to decreased muscle activity can arise from a combination of diminished osteoblast activity and enhanced osteoclastic resorption. In our opinion, murine model studies should be conducted to better understand the mechanism(s) of muscle/bone interactions in vivo, possibly using micro- or nano-CT imaging.

Previous studies of the influence of denture use on the amount of residual edentulous tissue were performed in one, two, or more limited regions.<sup>25,26</sup> This study evaluated not only the retromolar region, but also more anterior regions through the premolar. Generally, it was observed that RPD wearers had significantly reduced bone in the molar region when compared with the premolar region horizontally. One possible explanation for this may be that the MR starts at or near the lowest

**Table 2** Measurements of mandibular height and width at dentate and edentulous sites in four mandibular tooth regions (PM1, PM2, M1, M2) in RPD wearers and non-wearers. Superscripted letters indicate statistically significant differences ( $p < 0.05$ ) between values with the same letter

	Region	Alveolar height			Alveolar width from mylohyoid ridge		
		Dentate (mm $\pm$ SD)	Edentulous (mm $\pm$ SD)	Mean difference (%)	Dentate (mm $\pm$ SD)	Edentulous (mm $\pm$ SD)	Mean difference (%)
RPD non-wearers	PM1	27.9 $\pm$ 2.7	21.8 $\pm$ 2.5	<b>25.4<sup>b</sup></b>	10.6 $\pm$ 1.5	9.8 $\pm$ 1.2	7.5
	PM2	27.7 $\pm$ 2.5	21.9 $\pm$ 2.4	<b>20.9<sup>b</sup></b>	10.6 $\pm$ 1.5	9.4 $\pm$ 1.4	11.3
	M1	27.1 $\pm$ 2.4	21.1 $\pm$ 2.3	22.1	11.1 $\pm$ 1.2	9.8 $\pm$ 1.1	11.7
	M2	26.9 $\pm$ 2.1	20.8 $\pm$ 2.4	22.6	11.2 $\pm$ 1.4	9.9 $\pm$ 1.2	11.6
	Total mean	27.2 $\pm$ 2.4	21.4 $\pm$ 2.5	<b>22.7<sup>a</sup></b>	10.8 $\pm$ 1.4	9.8 $\pm$ 1.3	<b>9.1<sup>c</sup></b>
RPD Wearers	PM1	27.8 $\pm$ 2.2	19.9 $\pm$ 2.6	28.4	10.5 $\pm$ 1.4	9.2 $\pm$ 1.0	<b>12.3<sup>d</sup></b>
	PM2	27.9 $\pm$ 2.2	19.7 $\pm$ 2.6	29.3	10.8 $\pm$ 1.5	9.2 $\pm$ 1.0	14.8
	M1	27.3 $\pm$ 2.4	19.5 $\pm$ 2.4	30	11.1 $\pm$ 1.5	9.4 $\pm$ 1.1	15.3
	M2	27.0 $\pm$ 2.2	19.6 $\pm$ 2.5	27.4	11.4 $\pm$ 1.7	9.6 $\pm$ 1.1	<b>15.7<sup>d</sup></b>
	Total mean	27.5 $\pm$ 2.3	19.6 $\pm$ 2.5	<b>28.8<sup>a</sup></b>	10.9 $\pm$ 1.6	9.3 $\pm$ 1.1	<b>14.5<sup>c</sup></b>

part of the genial tubercles and passes posteriorly and superiorly, increasing in prominence, until the anterior portion of the ramus is reached. The MR is not as prominent in the premolar region as in the molar/retromolar region.<sup>25,26</sup> According to the anatomical distribution of the MR, resorption was found to be significantly higher in the molar region than in the premolar region in RPD wearers; however, further studies with larger study groups should be carried out, especially to examine mylohyoid muscle insertion and activity around these areas using electromyography.

In this study, patients were evaluated using CBCT imaging techniques. This method of imaging was proposed in the last decade for maxillo-craniofacial imaging.<sup>27-30</sup> Advantages of this imaging modality include lower radiation doses than traditional CT and the possibility of individualized, overlap-free reconstructions.<sup>28</sup> Dental CBCT can be recommended as a dose-sparing technique compared with standard medical CT scans for common oral and maxillofacial radiographic imaging tasks, especially for hard-tissue studies and representations. From the radiation point of view, CBCT examinations can be used instead of CT to evaluate jaw morphology and prosthetic needs. When 3D imaging is required to visualize anatomical structures, such as MR, submandibular fossa, or maxillary sinus localization, CBCT should be preferred over standard CT.

This study had several limitations. We did not investigate the duration of edentulism. Moreover, we did not divide the study participants into age groups (e.g., 40–49, 50–59,  $\geq 60$  years) because of insufficient patient numbers. To standardize the study, we examined only Kennedy Class II edentulous patients, and RPD wearers with  $\geq 5$  years of use. Thus, we could not evaluate the effect of different edentulism durations on alveolar resorption. According to a power analysis, to divide the sample as mentioned above, we should have  $\geq 20$  patients for each age group and edentulism period; however, because of strict standardizing, we included as many patients as we could find who fit the selection criteria of the study.

Further studies should be conducted with limitations on the edentulous period and with subdivision into age groups by decade. However, it should be noted that no patient in this

study had any bone disease; those with osteoporosis were excluded, according to previous reviews of the risk of bone loss in denture wearers.<sup>4,31,32</sup> Thus, it was concluded that the resorption observed in this study was caused by local factors rather than systemic factors, such as osteoporosis.

## Conclusions

Vertical and horizontal alveolar bone resorption was found to be higher in the RPD-wearing patients when comparing the dentate and edentulous sites.

## References

- Petrokovski J, Kaffe I, Arensburg B: Retromolar ridge in edentulous patients: clinical considerations. *J Prosthodont* 2007;16:502-506
- Klemetti E: A review of residual ridge resorption and bone density. *J Prosthet Dent* 1996;75:512-514
- Petrokovski J, Harfin J, Levy F: The influence of age and denture wear on the size of edentulous structures. *Gerodontology* 2003;20:100-105
- Carlsson GE: Responses of jawbone to pressure. *Gerodontology* 2004;21:65-70
- Xie Q, Ainamo A, Tilvis R: Association of residual ridge resorption with systemic factors in home-living elderly subjects. *Acta Odontol Scand* 1997;55:299-305
- Karaagaçlioglu L, Ozkan P: Changes in mandibular ridge height in relation to aging and length of edentulism period. *Int J Prosthodont* 1994;7:368-371
- Wyatt CC: The effect of prosthodontic treatment on alveolar bone loss: a review of the literature. *J Prosthet Dent* 1998;80:362-366
- Petrokovski J, Starinsky R, Arensburg B, et al: Morphologic characteristics of bony edentulous jaws. *J Prosthodont* 2007;16:141-147
- Merrot O, Vacher C, Merrot S, et al: Changes in the edentate mandible in the elderly. *Surg Radiol Anat* 2005;27:265-270
- Chrcanovic BR, Abreu MH, Custódio AL: Morphological variation in dentate and edentulous human mandibles. *Surg Radiol Anat* 2011;33:203-213

11. Koshino H, Hirai T, Ishijima T, et al: Influence of mandibular residual ridge shape on masticatory efficiency in complete denture wearers. *Int J Prosthodont* 2002;15:295-298
12. Campbell RL: A comparative study of the resorption of the alveolar ridges in denture-wearers and non-denture-wearers. *J Am Dent Assoc* 1960;60:143-153
13. Carlsson GE, Ragnarson N, Astrand P: Changes in height of the alveolar process in edentulous segments. Part II. A longitudinal clinical and radiographic study over 5 years of full upper denture patients with residual lower anteriors. *Sven Tandlak Tidsskr* 1969;62:125-136
14. Smith FW, Applegate OC: Roentgenographic study of bone changes during exercise stimulation of edentulous areas. *J Prosthet Dent* 1961;11:1086-1097
15. López-Roldán A, Abad DS, Bertomeu IG, et al: Bone resorption processes in patients wearing overdentures. A 6-years retrospective study. *Med Oral Patol Oral Cir Bucal* 2009;14:203-209
16. Canger EM, Celenk P: Radiographic evaluation of alveolar ridge heights of dentate and edentulous patients. *Gerodontology* 2012;29:17-23
17. Mori S, Sato T, Hara T, et al: Effect of continuous pressure on histopathological changes in denture-supporting tissues. *J Oral Rehabil* 1997;24:37-46
18. Reddy MS, Geurs NC, Wang IC, et al: Mandibular growth following implant restoration: does Wolff's law apply to residual ridge resorption? *Int J Periodontics Restorative Dent* 2002;22:315-321
19. Lestrel PE, Kapur KK, Chauncey HH: A cephalometric study of mandibular cortical bone thickness in dentulous persons and denture wearers. *J Prosthet Dent* 1980;43:89-94
20. Alajbeg IZ, Valentic-Peruzovic M, Alajbeg I, et al: The influence of dental status on masticatory muscle activity in elderly patients. *Int J Prosthodont* 2005;18:333-338
21. Alajbeg IZ, Valentic-Peruzovic M, Alajbeg I, et al: The influence of age and dental status on elevator and depressor muscle activity. *J Oral Rehabil* 2006;33:94-101
22. Ausk BJ, Huber P, Poliachik SL, et al: Cortical bone resorption following muscle paralysis is spatially heterogeneous. *Bone* 2012;50:14-22
23. Warner SE, Sanford DA, Becker BA, et al: Botox induced muscle paralysis rapidly degrades bone. *Bone* 2006;38:257-264
24. Sakata T, Sakai A, Tsurukami H, et al: Trabecular bone turnover and bone marrow cell development in tail-suspended mice. *J Bone Miner Res* 1999;14:1596-1604
25. George Y, Sadek L: A contribution to the topography of the mylohyoid ridge and its relation to the apices of posterior teeth. *Egypt Dent J* 1979;25:127-135
26. Moore KL, Agur MRA (eds): *Essential Clinical Anatomy* (ed 3). Philadelphia, Lippincott, Williams & Wilkins, 2007, pp. 601-605
27. Moreira CR, Sales MA, Lopes PM, et al: Assessment of linear and angular measurements on three-dimensional cone-beam computed tomographic images. *Oral Surg Oral Med Oral Pathol Oral Radiol Endod* 2009;108:430-436
28. Farman AG, Scarfe WC: Development of imaging selection criteria and procedures should precede cephalometric assessment with cone-beam computed tomography. *Am J Orthod Dentofacial Orthop* 2006;130:257-265
29. Brown AA, Scarfe WC, Scheetz JP, et al: Linear accuracy of cone beam CT derived 3D images. *Angle Orthod* 2009;79:150-157
30. Mozzo P, Procacci C, Tacconi A, et al: A new volumetric CT machine for dental imaging based on the cone-beam technique: preliminary results. *Eur Radiol* 1998;8:1558-1564
31. von Wowern N: General and oral aspects of osteoporosis: a review. *Clin Oral Investig* 2001;5:71-82
32. Dervis E: Oral implications of osteoporosis. *Oral Surg Oral Med Oral Pathol Oral Radiol Endod* 2005;100:349-356